

Two Case Reports of Pediatric Gastrointestinal Basidiobolus Treated Medically, With Literature Review

Abdulrahim M. Abdullahi¹, Walaa A. Alshenawy², Mohammed S. Alshahrani³, Othman F. Aljadoa¹, Sadeq AIDandan⁴, Mohammad AlShehri⁵

¹Pediatric Board, Infectious Disease Fellowship, King Fahad Medical City (KFMC), Pediatric department, infectious disease, Riyadh, KSA.

²Pediatric Board, Infectious Disease Fellowship, King Saud university medical city (KSUMC), Pediatric department, infectious disease, Riyadh, KSA.

³Pediatric Board, Infectious Disease Fellowship, Pediatric department, infectious disease, Khamis Mushiat, KSA.

⁴Anatomic pathologist & Neuropathologist, King Fahad Hospital, Pathology Department, Hafuf, KSA.

⁵Pediatric Infectious Disease Consultant, King Fahad Medical City (KFMC), Riyadh, KSA.

ABSTRACT

Basidiobolus is a rare fungus which leads to cutaneous and extra cutaneous manifestations such as gastrointestinal diseases that are associated with significant morbidity. Majority of cases in literature were reported from Saudi Arabia. So far no guideline exists for Basidiobolus management. Here we report two pediatric gastrointestinal Basidiobolus cases, both started on medical therapy alone. Furthermore, we conduct brief literature review that includes descriptive review of reported cases in the literature since 2013. So far 79 pediatric cases have been reported in the last 10 years. We noticed significant trending up of medical therapy in comparison with surgical therapy in last decade compared to previous reports before 2013. In addition to that, similar cure rate has been observed. We have reported increase in Voriconazole therapy popularity after decades of Itraconazole traditional use to treat Basidiobolus infection.

Keyword: Basidiobolus, basidiobolomycosis, Gastrointestinal, Pediatric, Child.

Introduction

Basidiobolus is a fungus, in order Entomophthorales [1]. It causes a rare disease that affect immunocompetent mainly [1]. It was known to cause skin and soft tissue infections, however recently increasing reports of emerging visceral involvement has been observed especially in gastrointestinal system [2]. It is found in environment in vegetation and organic debris [3]. It forms histologically septate hyphae which has main characteristic feature of the formation of an eosinophilic halo around the hyphae after hematoxylin and eosin staining (Splendore-Hoeppli phenomenon) [4]. Basidiobolus exist in wide

Geographic areas, especially in tropics [1]. Most published pediatric gastrointestinal cases were from Saudi Arabia [5], and a recent study showed further increased numbers in the last 10 years [6] in comparison to earlier reports [5]. Despite the relative long time since antifungal therapy has been used for Basidiobolus treatment, still no standardized therapy regimen. Also few data regarding antifungal susceptibilities exist (scattered case reports and few retrospective studies in the literature). Surgical intervention has been utilized more in earlier reports [5], however recently increase in medical treatment

Access this article online	
Quick Response Code:	Website: www.smh-j.com
	DOI: 10.54293/smhj.v4i3.110

Address for correspondence: Walaa Alshenawy, Pediatric Board, Infectious Disease Fellowship, King Saud university medical city (KSUMC), Pediatric department, infectious disease, Riyadh, KSA.

E-mail: bonbon_196@hotmail.com

Received: 1 May 2024 **Accepted:** 4 Sept 2024

This is an open access article by SMHJ is licensed under Creative Commons Attribution 4.0 International License.

(<https://creativecommons.org/licenses/by/4.0>)

Please cite this article as: Alshenawy W, Abdulrahim Mohamed Abdullahi, Mohammed Saad Alshahrani, Othman aljadoa, Alshehri M, AIDandan S. Two Case Reports of Pediatric Gastrointestinal Basidiobolus Treated Medically, With Literature Review. SMHJ [Internet]. 2024;4(3):159-168.

Two Case Reports of Pediatric Gastrointestinal Basidiobolus Treated Medically, With Literature Review

Alone has been observed. Pediatric gastrointestinal Basidiobolus cases before 2013 were estimated to be around 29 cases in a study from our center [5]. We have conducted literature review (using English literature in MIDLINE, using earlier mentioned keywords) that revealed 79 pediatric gastrointestinal Basidiobolus cases reported so far since 2013 [5]. We focused on available culture susceptibilities, treatment selected, rule of surgery and outcome. Furthermore, we report a two pediatric cases of gastrointestinal Basidiobolus successfully treated medically.

Case 1

A four-year-old boy from Tahama, a southwestern region of Saudi Arabia. He is known to have alpha thalassemia and Glucose-6-phosphate Dehydrogenase deficiency. He presented to the Emergency Department (ED) complaining of abdominal pain, abdominal distension, and weight loss for the previous 15 days. The disease started with abdominal pain, nausea, and diarrhea. Later, he developed a high-grade fever. Upon assessment in the ED, he was ill-looking with severe pain and dehydration. Initial vitals were: axillary temperature 38.6 °C, pulse 126 bpm, respiratory rate 31 per minute, oxygen saturation 99%, blood pressure 112/78 mmHg. Abdominal examination showed an obvious asymmetrical distention on the right side of the abdomen. The umbilicus was everted. When palpated, there was a generalized tenderness over the abdomen, more on the right side, with a palpable mass in the right pelvic region crossing the midline at the umbilicus. The mass was circumscribed, firm, tender, and dull on percussion measure about 5x5 cm, with rebound tenderness. His initial investigation in (Table 1) showed white blood cell count (high), hemoglobin (near the lower normal limit), platelet (high), eosinophils (high), elevated inflammatory markers, c-reactive protein and erythrocyte sedimentation rate. An abdomen ultrasound (US) was done, which showed a sizable heterogenous area posterior to the cecum and anterior to the psoas muscle extending to the pelvis, suggestive of a phlegmon formation associated with wall thickening of the cecum measuring 0.4 cm and adjacent small free fluid and surrounding turbid fluid could represent non-loculated collection (Figure 1). An abdominal CT scan showed an area of heterogeneous soft tissue density at the right lower quadrant posterior to the cecum. It spans about 4.2 x 1.5 x 3 cm in transverse, AP, and CC dimensions, respectively. The area is inseparable from the cecum, with significant cecal wall thickening reaching 1.4 cm and an overall phlegmonous appearance. Findings

could be related to a perforated appendix with a phlegmonous appearance representing appendicular mass (Figure 2). He was admitted for suspected appendicitis and started on empiric antibiotics. Despite triple antibiotics (Vancomycin, Ceftriaxone, and Metronidazole), there was no improvement. Repeated abdominal CT was done, which showed an Interval of significant worsening of the right lower quadrant heterogeneous area of soft tissue density measuring about 6.3 x 4.5 x 5 cm in transverse, AP, and CC dimensions, respectively. Associated with cecal wall thickening. (Figure 3). Repeated Computed Tomography (CT) of the abdomen was suggestive of lymphoma. A tissue biopsy was taken from the right mass near ascending colon, which showed chronic granulomatous Inflammation, necrosis, marked tissue eosinophilia, and fungal micro-organisms with broad hyposeptated hyphae and basidiospore consistent with basidiobolomycosis. (Figure 4: images A-F). A diagnosis of basidiobolomycosis was made. The family later reported that he likes to eat dirt, reflecting pica as a part of his primary diseases, which explains the source of the fungus. Voriconazole intravenously 9 mg/kg/dose every 12 hours for one day, then 8 mg/kg/dose every 12 hours as a maintenance dose. The child showed improvement; the fever subsided, and abdominal pain and distension improved. Later, he was shifted to oral voriconazole 8 mg/kg/dose every 12 hours and was discharged home with follow-up. After four months of outpatient care, the child's fever and abdominal pain improved without any palpable mass present. Follow-up investigation showed normal white blood cell count, normal hemoglobin, normal platelet count, and normal absolute eosinophils. He received a total of 4 months of therapy with complete resolution. Histopathologic features of basidiobolus ranarum. A: Splendore-Hoeppli bodies (arrows) are intensely eosinophilic granular material radiating around fungal hyphae which are pleomorphic with irregular non-parallel contours (H&E stain, 1000 magnification, oil immersion). B: The fungal hyphae are broad with thick walls (black arrow) and septated (hollow arrow), (Grocott Methenamine Silver stain, 1000 magnification, oil immersion). C: The fungal walls are rich in glycoprotein and stain strongly with (Periodic Acid Schiff stain, 1000 magnification, oil immersion). D: The basidiospores are spherical with foamy cytoplasm, round nucleus, and prominent nucleolus (H&E stain, 1000 magnification, oil immersion). E: The basidiospores are positive for Grocott Methenamine Silver stain (1000 magnification, oil immersion). F: The basidiospores

are positive for Periodic Acid Schiff stain (1000 magnification, oil immersion).

Case 2

A previously healthy two-and-a-half-year-old male from Aseer, a southwestern region in Saudi Arabia. Presented to the ED complaining of prolonged fever for the previous 3 weeks. The disease started with nonspecific gastrointestinal symptoms. Associated with night sweating but no history of weight loss. He had history of contact with animals (camel, cat, goat & dog) and raw milk ingestion. No contact with chronic cough patients. Upon physical examination, the patient was conscious, alert and looked well, but febrile. He had no respiratory distress, no dehydration, and no pallor or jaundice. Systemic examination was unremarkable except for Abdomen exam that showed non tender hepatomegaly. The initial laboratory workup showed WBCs (high), in which eosinophils percentage was (high), his Hb was (low) and his Platelets were (high). Inflammatory markers CRP and ESR were (High) (Table 1). Blood culture showed that Brucella and Malaria were negative. Abdominal US showed multiple hepatic focal lesions (at least three) ranging from 2.3 to 4 cm approximately) almost in the right lobe. Few enlarged porta hepatis lymph nodes (up to 26 mm). CT scan of abdomen showed two large heterogenous predominantly hyperdense hepatic lesions involving segment #8/5 and 4a/4b with few surrounding small satellite lesions, they measure $6.1 \times 6.1 \times 6.4$ cm in AP, ML and CC dimensions and $3.7 \times 5.1 \times 4.0$ cm in AP, ML and CC dimensions respectively. Periportal perivascular infiltration was seen within the right hepatic lobe. (Figure 5). Initially he was started on Metronidazole, Ceftriaxone, and Vancomycin, but the patient showed no improvement. So, he underwent liver biopsy which revealed histopathologic evidence of Basidiobolus infection. Subsequently, started on voriconazole and showed good improvement in his symptoms in few weeks and gradual regression of the mass after 4 months of therapy. So far completed 7 months.

Discussion

Presentation of Basidiobolus infection range from skin and subcutaneous manifestation to extra cutaneous cases (gastrointestinal and respiratory involvement). Overall gastrointestinal manifestation is considered a rare entity, however it leads to significant morbidity. This article focuses on gastrointestinal Basidiobolus. Up to our search we found 79 cases since 2013. Previously prevalence before 2013 was reported in a review study regarding reported pediatric gastrointestinal cases worldwide, they estimated to be

around 27 cases (most reported in last decade before study) majority were from Saudi Arabia [5]. In another review article, they search all gastrointestinal cases (Adult & children) from 1964 till 2014, they found 71 cases worldwide, majority from Saudi Arabia & US [7]. This highlights the importance of geography and patient origin that represent the clue in diagnosis. Similar finding observed in another study in US, as 11 out of 44 gastrointestinal Basidiobolus patients were from Saudi Arabia [8]. Study population were adult and pediatric and the search was up to 2010 [8]. In a study of pediatric case series included 12 pediatric patients, most common symptoms were fever, abdominal pain and palpable mass in exam, also they observed that half of the patients had weight loss, and only few had vomiting/diarrhea [9]. All diagnosis was made through histopathology, as histopathology was consistent with diagnosis in all patients reviewed in our literature review (case report/series). In contrast, cultures were only reported in 7 cases of which 5 were positive. Similar to previous observations noticed in another study were only one culture was positive out of 7 samples [9]. Furthermore, rarely molecular polymerase chain reaction (PCR) has been performed and no antibodies testing were done. Interestingly, it was found only one case in UK in which molecular PCR and fungal sequencing were performed. It facilitated quick identification and subsequent modification of therapy [10]. Similarly, one case was reported before 2013 in which PCR was performed [11]. Other important diagnostic feature clue was Eosinophilia. It is a challenge diagnosis; most patients presented with mass and some had surgical acute abdomen manifestations. Differential diagnosis includes other serious conditions such as malignancy. So majority of patients were diagnosed after invasive intervention as it was observed that diagnosis was made during surgical excision in most of the patients; in 37 out of 44 patients [8]. So far 5 cases considered as Proven cases in which typical gastrointestinal clinical and radiological manifestations as well as culture or PCR (from tissue biopsy) were positive. On the other hand, other cases fit probable if they show typical gastrointestinal clinical and radiological manifestations as well as histopathology characteristics. We can consider label patients as possible if they have epidemiologic data (reside in endemic areas), have typical gastrointestinal clinical and radiological manifestations, and have other supporting data such as eosinophilia. Review of culture/sensitivity show significant limitations. It was

Two Case Reports of Pediatric Gastrointestinal Basidiobolus Treated Medically, With Literature Review

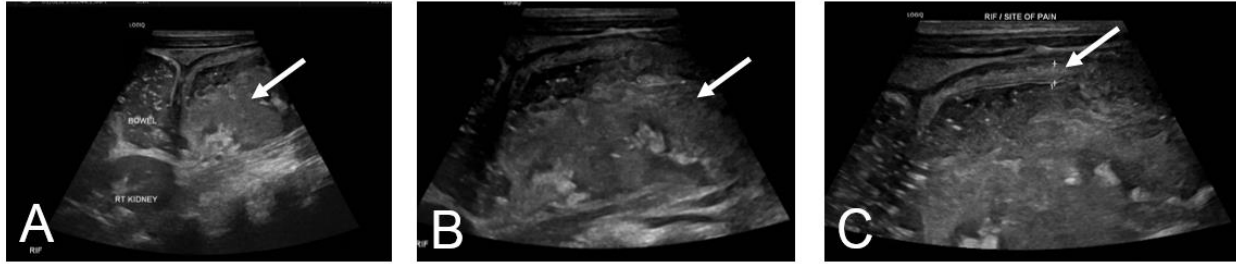


Figure 1: US Abdomen showing: A: large heterogenous area posterior to the cecum and anterior to the psoas muscle extending to the pelvis. B: Magnified picture of the mass. C: wall thickening of the cecum measuring 0.4 cm.

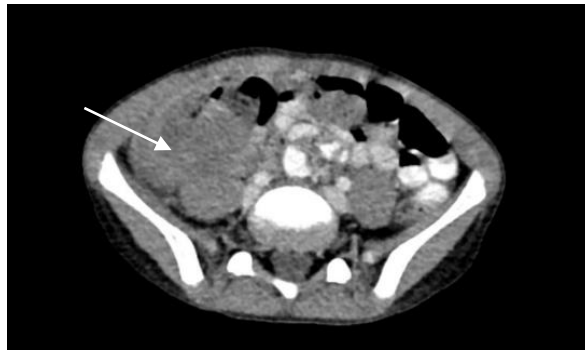


Figure 2: The initial abdominal CT scan showed an area of heterogeneous soft tissue density at the right lower quadrant posterior to the cecum. It spans about 4.2 x 1.5 x 3 cm in transverse, AP, and CC dimensions, respectively.

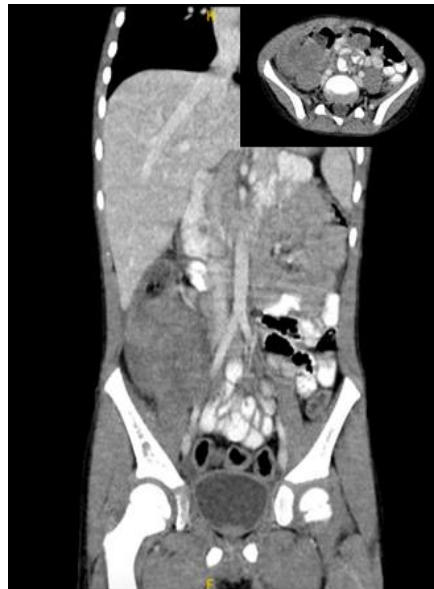

Figure 3: The second Abdominal CT showed worsening of the right lower quadrant heterogeneous area of soft tissue density measuring about 6.3 x 4.5 x 5 cm in transverse, AP, and CC dimensions, respectively.

Two Case Reports of Pediatric Gastrointestinal Basidiobolus Treated Medically, With Literature Review

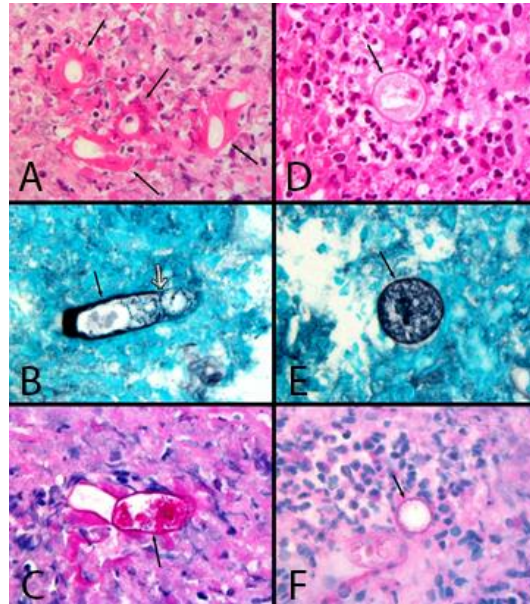


Figure 4: Case 1 Histopathology slides.

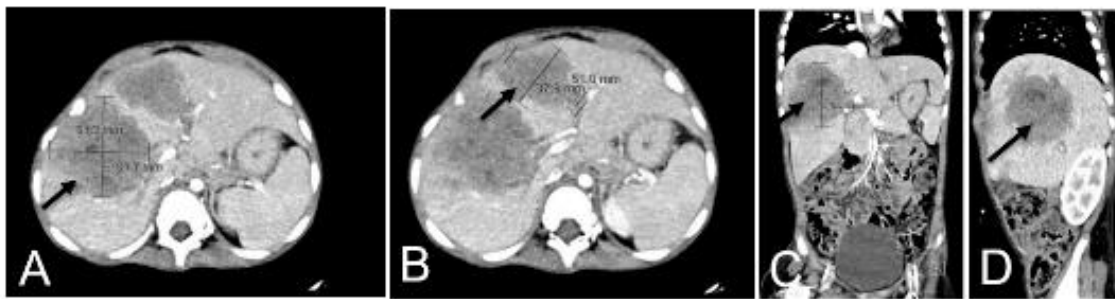


Figure 5: (A-D): There are two large heterogenous predominantly hyperdense hepatic lesions involving segment #8/5 and 4a/4b with few surrounding small satellite lesions, they measure 6.1 × 6.1 × 6.4 cm in AP, ML and CC dimensions and 3.7 × 5.1 × 4.0 cm in AP, M

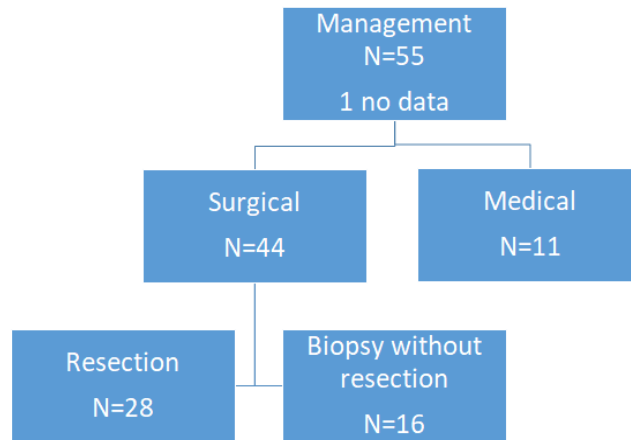


Figure 6: Literature review summary of pediatric gastrointestinal basidiobolus cases. Medical therapy collectively (without resection N=27), 24 cured, 1 died, (2 has no data). From those with surgical resection: 23 cured, 2 improving, 3 died. A study of 25 patient

Two Case Reports of Pediatric Gastrointestinal Basidiobolus Treated Medically, With Literature Review

Table 1: Laboratory investigations for case 1 and 2.

Lab	Case 1	Case 2	Standard range
White blood cell count (WBC)	24.8	18	(5 to 10) $10^3/\mu\text{L}$
Hemoglobin (HB)	10	7.5	(9.5-14) g/dL
Platelet (PLT)	727	780	(150-400) $10^9/\text{L}$
Eosinophils count (EA#)	3.48	-	(50-500) $10^3/\mu\text{L}$
Eosinophils percentage (EA %)	14%	12.8%	(1-4) %
C-reactive protein (CRP)	54.8	9	(1-3) mg/dL
Erythrocyte sedimentation rate (ESR)	89	120	(\leq 10) mm/hr

Two Case Reports of Pediatric Gastrointestinal Basidiobolus Treated Medically, With Literature Review

Table 2: Laboratory investigations for case 1 and 2.

Antifungal* N=42	Agent used	Outcome	Duration for those cured (Range)
Monotherapy N = 38	Voriconazole N=12	11 cured (6 had resection), 1 died (had a resection)	Range (minimum 6 months, maximum up to 12 months), except one patient treated for 6 weeks**.
	Itraconazole N=24	23 cured (14 had resection), 1 died (had a resection).	Range (minimum 6 months, maximum up to 12 months)
	Amphotericin N=2	Improving (1), Died (1), both had a resection	3 months
Combination* N = 4 All with itraconazole, except one.	Ampho + Azole N=2	Both cured (both had resection)	One for 6 months, and the other patient for 1 year
	Ampho + Azole + Iodide N=1 (Ampho then switch to Azole) + Azole + Iodide + Bactrim N=1	Both cured (both had resection)	One for 3 months, And the other patient for 4 months

* One patient had not received medical therapy (died). We excluded a study that included 25 patients who received voriconazole but no detailed numbers of monotherapy vs combination or surgical details. Another study of 12 patients didn't mention the therapy. And a case report of one patient had no complete data.

**One patient was treated for 6 weeks (stopped azoles after intolerance); however, he was cured.

Not performed routinely in majority of reports, so interpretation is unknown due to unavailability of international breakpoint guideline for this rare fungus. Older studies review revealed a large study report testing of 9 isolates showed azoles to have the best performance in general, and among azoles it was noticed that Itraconazole had the lowest MIC mean in comparison with other antifungal drugs [12]. It is worth mention, amphotericin showed relatively low MIC mean as well [12]. In the same line another study of 2 isolates, showed MIC of Itraconazole was lower than Amphotricin (however it was still low for both) [13]. However old study showed that Amphotericin was susceptible only in less than 50% (in 12 isolates, in which 4 were human isolates) [14]. In another study in which 4 isolates tested: all (4/4) resistant to Amphotricin B and flucytosine, 2/4 resistant to fluconazole, and 1/1 to caspofungin. Regarding Azoles group Itraconazole was sensitive in all the 4 samples, while 1 sensitive to voriconazole & posaconazole [8]. It is worth mentioning, culture was positive in (71%) in 24 patients whom culture information was mentioned. Another study of one isolate that had high MIC for azoles (except clotrimazole, not including voriconazole), and low Amphotricin MIC [15]. Interestingly in our review, we come cross one of rare pediatric case that report sensitivity for clinical sample. It showed voriconazole, posaconazole resistance while other azoles (itraconazole and isavoconazole) were sensitive. In the same study Echinocandin and Amphotericin reported to be sensitive [10]. Despite few basidiobolus lab data since approval voriconazole which was early 2000s, we noticed increase in clinical reports of clinical successful use of voriconazole. We have reviewed management in new studies since 2013. Our literature review of pediatric gastrointestinal basidiobolus showed 24 case reports/series, 55 cases in retrospective studies (Figure 6). Total of 79 cases so far since 2013 (Table 2). Majority of patients had surgical intervention, however not all had surgical resection of the mass. We found a significant number of patients underwent surgery for diagnostics without any resection. Some patients were found to have unresectable mass, due to extensive tissue and vessel adhesions, and despite that they were managed medically successfully. Remaining patients managed medically, after confirmation of diagnosis with help of less invasive procedures (such as interventional

radiology) as described in (Table 2). Furthermore, we will discuss two retrospective studies. In a retrospective study includes 12 patients study, managed patients (without resection of mass) as it was difficult. Despite all being treated medically (or limited surgical intervention for complications), 11 patients out of 12 cured [9]. In contrast to previous observation, a study that included 18 patients majority had surgical intervention (15 out of 18). However, 13 patients had resection [16]. The largest reported study so far in pediatric (25 patients study) had no detailed description of management or surgical, however they stated almost all patients received voriconazole with favorable outcome [6]. Management: in old before 2013 studies 1-Surgical: Earlier reports emphasize on surgical intervention. In the earlier mentioned Saudi pediatric study in 2013, 25 out of 29 patients underwent surgery. However, only 21 patients have had a surgical resection [5]. Remaining were either had unresectable mass (majority died) or had only biopsy. In the same line, in a study that included adults in the US, 84% of patients underwent surgery [8]. In a literature review article before 2014, 71 cases across all ages were reported, the majority (59 cases) underwent surgery [7]. we have reviewed medical therapy used before 2013. In a pediatric study in 2013, regarding medical therapy used (Amphotericin used in 22 patients as combination agent, of which in 19 patients it was used with itraconazole combination), voriconazole was used only once (in combination therapy). In addition to that, they have reported the first case using monotherapy voriconazole [5]. Also the US adult study in 2010, showed that Itraconazole was used in most of the patients 73%, while Amphotericin was used in 22% and voriconazole in 5% only (in 25 patients with available information) [8]. So we found Itraconazole was popular again in our review of 24 cases after 2013 despite its variable metabolism. However, it is increasingly successfully used as we found 10 cases, which could be explained by late voriconazole approval in the 2000s. We can notice comparable cure cases with respect to similar surgical intervention rate and duration range (from 6 months to 1 year). Our case (number2) has a short duration (check other supporting cases). Surprisingly, the shortest reported case was treated with voriconazole for 6 weeks [10]. Duration in older review: in adult US study mean duration of antifungal therapy was 8 months (in 25 patients with available

information) [8]. In same study, the observed outcome showed 80% survived (death in 8, however 4 did not receive antifungal therapy, and 3 was on Amphotericin) [8]. In a pediatric study of 2013 of 29 cases, 8 patients died, 19 cured (however no duration or follow up information available) [5]. In our review of 79 cases, 70 cases cured, 2 improving, and 4 deaths which could represent improvement of care (3 were not reported). Limitation due to the nature of descriptive study, it is unknown the causality or association. Duration of follow up could be a limitation.

Conclusion

Basidiobolus is a rare fungal infection that seems to be endemic to our region. It poses challenge in diagnosis. However helpful clue for diagnosis could be abdominal mass with Eosinophilia in children from endemic region (southwestern in Saudi Arabia). As we have described increase in reported successful medical management, we could emphasize that successful treatment can be achieved without need for surgical intervention. Continuing to monitoring and reporting treatment used would help in creating standard management guideline.

Conflict of Interest

None

Funding

None

References

1. Shaikh N, Hussain KA, Petraitiene R, Schuetz AN, and Walsh TJ. Entomophthoromycosis: A neglected tropical mycosis. *Clin Microbiol Infect.* 2016;22(8):688-694. doi:10.1016/j.cmi.2016.04.005
2. El-Shabrawi MH, Arnaout H, Madkour L, and Kamal NM. Entomophthoromycosis: A challenging emerging disease. *Mycoses.* 2014;57 Suppl 3:132-137. doi:10.1111/myc.12248
3. Gugnani HC. A review of zygomycosis due to *Basidiobolus ranarum*. *Eur J Epidemiol.* 1999 Nov;15(10):923-9. doi:10.1023/a:1007656818038
4. Mendoza L, Vilela R, Voelz K, Ibrahim AS, Voigt K, and Lee SC. Human Fungal Pathogens of Mucorales and Entomophthorales. *Cold Spring Harb Perspect Med.* 2014 Nov 6;5(4):a019562. doi:10.1101/cshperspect.a019562
5. Al Asmi MM, Faqeehi HY, Alshahrani DA, and Al-Hussaini AA. A case of pediatric gastrointestinal basidiobolomycosis mimicking Crohn's disease. A review of pediatric literature. *Saudi Med J.* 2013;34(10):1068-1072 PMID: 24145943
6. Ghazwani SM, Arishi HM, Dhayhi NS, et al. Pediatric Gastrointestinal Basidiobolomycosis: A Retrospective Study from Jazan Province, Saudi

- Arabia. *Infect Drug Resist.* 2023;16:4667-4676. Published 2023 Jul 18. doi:10.2147/IDR.S416213
7. Geramizadeh B, Heidari M, and Shekarkhar G. Gastrointestinal Basidiobolomycosis, a Rare and Under-diagnosed Fungal Infection in Immunocompetent Hosts: A Review Article. *Iran J Med Sci.* 2015;40(2):90-97. PMID: 25821287; PMCID: PMC4359942.
8. Vikram HR, Smilack JD, Leighton JA, Crowell MD, and De Petris G. Emergence of gastrointestinal basidiobolomycosis in the United States, with a review of worldwide cases. *Clin Infect Dis.* 2012 Jun;54(12):1685-91. doi: 10.1093/cid/cis250. Epub 2012 Mar 22. PMID: 22441651
9. Al Haq AM, Rasheedi A, Al Farsi M, Mehdar A, Yousef Y, Rasheed K, and Binyahib S. Gastrointestinal Basidiobolomycosis in pediatric patients: A diagnostic dilemma and management challenge. *Int J Pediatr Adolesc Med.* 2021 Dec;8(4):212-220. doi: 10.1016/j.ijpam.2020.05.003
10. Kurteva E, Bamford A, Cross K, Watson T, Owens C, Cheng F, et al. Colonic Basidiobolomycosis-An Unusual Presentation of Eosinophilic Intestinal Inflammation. *Front Pediatr.* 2020 Apr 21;8:142. doi: 10.3389/fped.2020.00142. PMID: 32373558; PMCID: PMC7186448
11. El-Shabrawi MH, Kamal NM, Kaerger K, and Voigt K. Diagnosis of gastrointestinal basidiobolomycosis: a mini-review. *Mycoses.* 2014;57 Suppl 3:138-143. doi:10.1111/myc.12231
12. Josep Guarro, Carme Aguilar, Isabel Pujol, In-vitro antifungal susceptibilities of *Basidiobolus* and *Conidiobolus* spp. strains, *Journal of Antimicrobial Chemotherapy.* 1999;44(4):557-560, <https://doi.org/10.1093/jac/44.4.557>
13. Lyon GM, Smilack JD, Komatsu KK, et al. Gastrointestinal basidiobolomycosis in Arizona: clinical and epidemiological characteristics and review of the literature. *Clin Infect Dis.* 2001;32(10):1448-1455. doi:10.1086/320161
14. Yangco BG, Okafor JI, and TeStrake D. In vitro susceptibilities of human and wild-type isolates of *Basidiobolus* and *Conidiobolus* species. *Antimicrob Agents Chemother.* 1984 Apr;25(4):413-6. doi: 10.1128/AAC.25.4.413. PMID: 6329078; PMCID: PMC185542
15. Mohd Nizam T, Binting RA, Mohd Saari S, Kumar TV, Muhammad M, Satim H, et al. In Vitro Antifungal Activities against Moulds Isolated from Dermatological Specimens. *Malays J Med Sci.* 2016 May;23(3):32-9. PMID: 27418867; PMCID: PMC4934716
16. Shreef K, Saleem M, Saeedd MA, and Eissa M. Gastrointestinal Basidiobolomycosis: An Emerging, and A Confusing, Disease in Children (A Multicenter

Two Case Reports of Pediatric Gastrointestinal Basidiobolus Treated Medically, With Literature Review

Experience). *Eur J Pediatr Surg.* 2018;28(2):194-199.
doi:10.1055/s-0037-1598104