

The Manifestations and Complications of X-linked Hypophosphatemia in Saudi Arabia: A Retrospective Study

Afaf AlSagheir¹, Bassam Bin Abbas¹, Reem AlRasheed², Rufaydah AlKhowaiter¹, Malak AlTewerki³

¹MBBS, MD, Department of Paediatrics, King Faisal Specialist Hospital and Research Center, Riyadh, KSA.

²MBBS, MD, Department of Paediatrics, King Fahad Medical City, Riyadh, KSA.

³MBBS, MD, Adult Neurology Department, Neuroscience Centre, King Faisal Specialist Hospital and Research Centre, Riyadh, KSA.

ABSTRACT

Background: X-linked hypophosphatemia (XLH) is a genetic disease of phosphate metabolism in which inactivating mutations of the phosphate regulating endopeptidase homolog, X-linked (PHEX) gene lead to local and systemic effects. In our pediatric clinics, XLH was observed to be associated with multiple complications despite conventional treatment. There is a need for novel treatment modalities to prevent disease progression and aid in the resolution of symptoms. This study aimed to understand the manifestations and complications of XLH.

Methods: This retrospective chart review was undertaken on all patients with XLH who were followed up at the Endocrinology Clinics in King Faisal Specialist Hospital and Research Center (KFSHRC) in Saudi Arabia. The study was conducted by reviewing the medical files of those patients.

Results: All the patients (N=24) who were included in this study had PHEX gene mutations. The mean age was 18.7±13.6 years and 66.7% were females. The mean height standard deviation score (HSDS) was 2.96 (-5.25 to -0.97) and 12 patients reached their final height (mean final HSDS, -3.28 [-1.39 to 5.39]). Skeletal deformities (mainly genu varum) were observed in 70.8% of the patients and 29.2% had craniosynostosis; 54.2% had undergone corrective osteotomy. Hyperparathyroidism was observed in 54.2% of the patients and 45.8% of the patients had nephrocalcinosis (grades 2/3).

Conclusions: In our study, a majority of the XLH patients suffered from complications arising from the use of conventional therapy, thus indicating the need for novel treatment modalities for these patients. Additionally, no correlation between genotype and phenotype was found.

Keyword: X-linked hypophosphatemia; PHEX gene mutation; Alkaline phosphatase; Stunted growth; Skeletal deformity; Parathyroid hormone; Nephrocalcinosis; Saudi Arabia.

Introduction

X-linked hypophosphatemia (XLH) is a genetic familial disease characterized by low phosphate levels in the blood, resulting in a spectrum of signs and symptoms. The disorder that occurs as a result of

Mutations in the phosphate regulating endopeptidase homolog, X-linked (PHEX) gene on the X chromosome. Inheritance is X-linked dominant [1]. Prevalence of the disorder is estimated at approximately 1 in 20,000 to 1 in 60,000 live births

Access this article online	
Quick Response Code:	Website: www.smh-j.com
	DOI: 10.54293/smhj.v4i3.111

Address for correspondence: Afaf AlSagheir, MBBS, MD, Department of Pediatrics (MBC-58), King Faisal Specialist Hospital and Research Centre. Al Mathar Ash Shamali, PO Box 3354, Riyadh, 11211, Saudi Arabia.

E-mail: ASagheir@kfshrc.edu.sa

Received: 10 Jun 2024 **Accepted:** 7 Sept 2024

This is an open access article by SMHJ is licensed under Creative Commons Attribution 4.0 International License.

<https://creativecommons.org/licenses/by/4.0>

Please cite this article as: AlSagheir A, Bin Abbas B, AlRasheed R, AlKhowaiter R, AlTewerki M. The Manifestations and Complications of X-linked Hypophosphatemia in Saudi Arabia: A Retrospective Study. SMHJ [Internet]. 2024;4(3):137-149.

The Manifestations and Complications of X-linked Hypophosphatemia in Saudi Arabia: A Retrospective Study

[2, 3]. PHEX expression is predominantly in osteoblasts and leads to suppression of serum Fibroblast Growth Factor 23 (FGF23) [1]. FGF23 acts on receptors located in the proximal convoluted tubule causing phosphate wasting and hypophosphatemia. In addition, PHEX gene mutations can also cause decreased absorption of phosphate in the gut [4]. The low levels of phosphate further result in defective bone mineralization, leading to impaired osteoblastic function. Patients with XLH also possess higher levels of 1,25-dihydroxyvitamin D3 [5]. Symptoms such as bowing of the lower legs (genu varum), stunted growth, delayed walking, and/or abnormal walking gait in the early years of life typically lead to a diagnosis in pediatric patients [6]. Other common symptoms in children include bone pain, rachitic rosary, frontal bossing and dolichocephaly with parietal flattening. In rare cases, patients can be diagnosed with hearing impairment, intercranial hypertension, craniosynostosis or type 1 Chiari malformations [6, 7, 8]. Patients with suspicion of XLH or with clinical signs and symptoms undergo genetic testing [9]. This is usually done in addition to the routine laboratory tests such as serum phosphate, serum calcium, and 1,25-dihydroxyvitamin D3 [5]. Supplementation with oral phosphate and active vitamin D is the initial treatment for XLH and helps to improve the condition, reduces the development of dental abscesses, as well as slowing down progressive growth failure. However, the treatment is ineffective in a considerable number of patients due to non-adherence resulting from unpleasant taste and/or associated adverse effects such as gastrointestinal discomfort, nephrocalcinosis in addition to hyperparathyroidism [7, 8]. As many as 66% of children with XLH will need lower limb surgery [10-12]. Efficacy of conventional therapy is limited by increased FGF23 levels and renal phosphate wasting [13-15]. Therefore, XLH patients need to be closely monitored and there is a constant need for safer and more efficacious therapies to manage the disease [7]. Burosumab, a recombinant human IgG1 monoclonal antibody, binds to and inhibits excess FGF23 [16, 17]. This novel treatment has been approved by the United States Food and Drug Administration for use in pediatric XLH patients who are 6 months and older and has shown promising results [18]. Burosumab has been successfully tested in various phase II and phase III clinical trials in children with XLH, and has demonstrated improvements in biochemical parameters and specified clinical outcomes [19]. This retrospective chart review aims to understand the

manifestations and complications of XLH in patients who were followed up at King Faisal Specialist Hospital and Research Center (KFSHRC) in Riyadh, Saudi Arabia.

Methods

Study design: This retrospective, observational, chart review study evaluated the manifestations and complications of XLH by reviewing the medical files of all XLH patients who were followed up at the Endocrinology Clinics in KFSHRC in Riyadh, Saudi Arabia, between 2005 and 2021.

Patients' selection: Data for 24 patients who were followed up, for the specified period, was collected. Patients with XLH, of all ages, who had a confirmed PHEX gene mutation were included. Patients diagnosed with nutritional rickets or vitamin D-dependent rickets, and patients with suspected malignancies that would impact the course of the condition, were excluded from the study.

Parameters for data analysis: Various parameters were taken into consideration for the purpose of data analyses. This included demographic data, such as age and gender, clinical presentation, and genetic mutations. Laboratory results at diagnosis, including alkaline phosphatase (ALP) and serum phosphate levels, as well as details regarding complications related to therapy were also considered.

Patient's growth: The growth of the patients was calculated in terms of height and was analyzed and documented using Centers for Disease Control and Prevention (CDC) growth charts and height standard deviation score (HSDS). We have reported the latest documented HSDS of '-1.5 to -2' as 'mild short stature' and a HSDS of '-2 or more' as 'severe short stature'. In patients aged above 14 years, the height was documented as 'final height' if they showed no change in height in the past 1 to 2 years.

Complications of the disease: This parameter was divided into skeletal complications, endocrine complications, and renal complications. Skeletal complications were analyzed using radiographs and the results were compared with those at the time of presentation, with the findings being correlated with the type of mutation that was identified. Endocrinological complications were assessed by measuring the parathyroid hormone (PTH) levels. Patient data was evaluated for reports of renal stones identified by regular ultrasonography scans, and incidences of renal stone formation were documented. **Statistical methods:** Analysis involved the use of descriptive statistics: mean, standard deviation (SD) and range were calculated for continuous variables,

The Manifestations and Complications of X-linked Hypophosphatemia in Saudi Arabia: A Retrospective Study

whilst frequencies with proportions were reported for categorical variables.

Ethics: Ethical approval for the study was gained from the Research Advisory Council at King Faisal Specialist Hospital and Research Center (RAC #2211051). The study adheres to the guidelines and regulations at KFSHRC. All treatment plans and clinical investigations formed part of each patient's on-going medical care. Informed consent was obtained from all patients or their guardians.

Results

Between 3 December 2018 and 24 March 2021, data from 24 patients were reviewed and analyzed. Of these 24 patients, 16 (66.7%) were females and 8 (33.3%) were males, and included 5 families. The mean age was 18.7 ± 13.6 years and the type of PHEX gene mutation was available for all patients (Table 1). Diagnostic evaluation in these patients was prompted either due to clinical manifestations of lower limb deformity or due to a positive family history of the disease. Diagnostic laboratory tests at baseline reported a mean (\pm SD) fasting blood phosphate level of 0.63 ± 0.11 mmol/L (range, 0.43-0.9 mmol/L), mean blood calcium level of 2.32 ± 0.1 mmol/L, mean ALP level of 584 ± 82 U/L (range, 484-762 U/L). No differences in terms of the prognosis and complications, in relation to the mutation type, was observed among the patients. Almost all patients had stunted growth of varying degrees. The mean HSDS was -2.96 (range, -5.25 to 0.97). Twelve patients reached their final height, with their mean final HSDS being -3.28 (-1.39 to 5.39). Mild growth stunting was observed in 4 (16.7%) patients (HSDS, -1.5 to -2.0). Moderate-severe growth stunting was observed in 20 (83.3%) patients (HSDS, less than -2), of whom 6 (30.0%) had HSDS less than -4 (Figure 1). In terms of complications, 17 (70.8%) patients suffered from skeletal complications (Figures 2-4). Of these, 10 (41.7%) patients had genu varum, 7 (29.2%) had genu valgum, and 7 (29.2%) had craniosynostosis, and 13 (54.2%) patients had undergone corrective osteotomy. All the patients suffered from osteopenia and short stature in general. Hyperparathyroidism was observed in 13 (54.2%) patients and 4 (16.7%) patients had parathyroid adenoma. All the patients had undergone parathyroidectomy. Nephrocalcinosis was detected in 11 (45.8%) patients and was mainly grade 2/3 (Figure 5). Dental problems were noted in most patients (Table 2). Two (8.3%) patients had Chiari malformation and required decompression surgery.

Discussion

This single-center study retrospectively assessed the manifestations and complications of XLH in patients in KFSHRC in Riyadh, Saudi Arabia. Laboratory findings, radiographs, and surgical history of 24 patients were reviewed. The height of the patients was estimated using HSDS to evaluate growth stunting and its degree of severity. Two-thirds (66.7%) of the patients were females. Findings from genetic testing had confirmed that presence of PHEX gene mutations in all the patients. This included variants of the PHEX gene mutation with different legacy names. Although other clinical studies have indicated that female patients with XLH were mildly affected in comparison to males [20, 21], no differences in the phenotype of both sexes were observed in this study. Almost all the patients had stunted growth (overall mean HSDS, 2.96), with 83.3% having moderate-severe growth stunting (HSDS less than 2) and 25.0% having an HSDS less than 4. These findings are comparable to other studies. An average HSDS of -2.2, -1.4, and -2.4 was reported at 4.4, 9.9 and 17.6 years, respectively, among patients treated with calcitriol and phosphate supplementation at Otto von Guericke University Magdeburg in Germany [22]. In untreated XLH patients the lowest HSDS reported was -3.2 at a mean age of 4.3 years [22]. In a Spanish study, the mean SDS was reported as -1.89 for 40 pediatric patients with XLH, 55% of which had moderate-severe growth stunting [23]. Furthermore, children at the Hospital for Sick Children in Canada who were treated before they developed the symptoms of rickets showed lower HSDS compared to children treated after they developed the symptoms of rickets, with HSDS values of -0.4 and -1.7 at treatment initiation, -0.7 and -1.8 after one year of treatment and -0.2 and -1.2 at predicted adult height, respectively [24]. Growth stunting can be attributed either to the type of PHEX gene mutation present, or to the patients' level of commitment and adherence to treatment. However, in this study, stunted growth was observed even among patients who were committed and compliant to treatment. Skeletal complications, including genu varum (41.7%), genu valgum (29.2%), craniosynostosis (29.2%), frontal bossing (4%), and recurrent fractures (4%) were observed in most of the patients. Over half the patients (54.2%) had undergone corrective osteotomy. These radiological symptoms of rickets are common in XLH patients in the region, contributing to the burden of the disease [25]. Previous literature has indicated that some XLH patients, who were treated with supplements, had higher PTH levels

The Manifestations and Complications of X-linked Hypophosphatemia in Saudi Arabia: A Retrospective Study

Table 1: Patient characteristics at diagnosis.

Patient	Age (years)	Sex	<i>PHEX</i> gene mutation	Clinical presentation	Serum phosphate (mmol/L)	Serum phosphate (mmol/L)	ALP (U/L)	PTH (ng/L)*	Final HSD S
#1	19	Female	c.2237G>T: (p.Cys746Phe)	Bilateral genu varum at 3 years of age	0.70	2.25	698	49	-2.11
#2	14	Male	c.2237G>T: (p.Cys746Phe)	Investigated because of family history	0.55	2.33	595	53	-2.46
#3	18	Male	c.2237G>T: (p.Cys746Phe)	Investigated because of family history	0.65	2.39	517	66	-1.96
#4	9	Female	c.2237G>T: (p.Cys746Phe)	Investigated because of family history	0.6	2.21	495	39	-3.23
#5	12	Female	del Exon 19_exon 20 ALPL exon6.c.582T>C, pro194pro	Investigated because of family history	0.7	2.23	762	60	-1.75
#6	23	Male	del Exon 19_exon 20 ALPL exon6.c.582T>C, pro194pro	Bilateral genu varum at 4 years of age	0.53	2.38	743	59	-2.1
#7	10	Male	del Exon 19_exon 20 ALPL exon6.c.582T>C, pro194pro	Investigated because of family history	0.66	2.4	551	48	-4.15
#8	7	Male	c.2237 G>T (p.Cys746Phe (C746F))	Investigated because of family history	0.91	2.34	553	52	-0.97
#9	11	Male	Duplication of exon 17 in <i>PHEX</i> gene	Bilateral genu varum at 17 months of age	0.7	2.29	576	49	-1.39
#10	15	Female	duplication in exon 3	Progressive bilateral genu varum at 2 years of age	0.67	2.36	500	57	-4.5
#11	16	Female	c.2239 C>T (R747X)	bilateral genu varum at 2 years of age	0.5	2.35	489	49	-3.91
#12	24	Female	c.2239 C>T (R747X)	Investigated because of family history	0.63	2.22	830	59	-5.25
#13	9	Female	c.2239 C>T (R747X)	Bilateral genu varum at 2 years of age	0.74	2.39	484	63	-3
#14	23	Female	c.2239 C>T (R747X)	Investigated because of family history	0.78	2.32	540	45	-3.26

The Manifestations and Complications of X-linked Hypophosphatemia in Saudi Arabia: A Retrospective Study

Patient	Age (years)	Sex	<i>PHEX</i> gene mutation	Clinical presentation	Serum phosphate (mmol/L)	Serum phosphate (mmol/L)	ALP (U/L)	PTH (ng/L)*	Final HSD S
#15	20	Female	c.2239 C>T (R747X)	Investigated because of family history	0.50	2.41	650	49	-4.2
#16	10	Female	c.2239 C>T (R747X)	Bilateral genu varum at 2 years of age	0.56	2.38	560	37	-3.17
#17	17	Male	c.2239 C>T (R747X)	Bilateral genu varum at 3 years of age	0.62	2.43	540	57	-5.39
#18	4	Female	c.2239 C>T (R747X)	Investigated because of family history	0.65	2.34	656	61	-2.2
#19	43	Female	c.2239 C>T (R747X)	Bilateral genu varum at 3 years of age	0.59	2.33	650	38	-3.38
#20	52	Female	c.2239 C>T (R747X)	Investigated because of family history	0.56	2.13	534	34	-3.7
#21	20	Male	c.2239 C>T (R747X)	Investigated because of family history	0.54	2.43	564	43	-3.16
#22	32	Male	c.2239 C>T (R747X)	Investigated because of family history	0.43	2.37	490	36	-3.1
#23	53	Female	c.2239 C>T (R747X)	Investigated because of family history	0.76	2.27	685	52	-4
#24	8	Female	c.2239 C>T (R747X)	Bilateral genu varum at 2 years of age	0.59	2.41	498	48	-2.93

ALP: alkaline phosphatase; HSDS: height standard deviation score; PTH:

The Manifestations and Complications of X-linked Hypophosphatemia in Saudi Arabia: A Retrospective Study

Table 2: Compliance to medication, surgical corrections, and renal, skeletal, dental, and thyroid complications among the participants.

Patient	Compliance to medication	Renal status	PTH (ng/L)*	Surgical correction	Skeletal and dental complications
#1	Good compliance	Bilateral grade 2 medullary nephrocalcinosis	Normal	Correction of genu valgum and epiphysiodesis of bilateral distal femur growth	Short stature, osteopenia, and genu valgum
#2	Poor compliance	Bilateral grade 2 medullary nephrocalcinosis	95-157	No	Short stature, osteopenia dental abscesses, dental caries, and mild bilateral genu varum
#3	Poor compliance	Normal	Normal	No	Short stature, osteopenia, mild bilateral genu varum, brachiocephalic craniosynostosis, and frontal bossing and proptosis
#4	Poor compliance	Bilateral mild medullary nephrocalcinosis	80-120	No	Short stature, osteopenia, deep dental caries, Persistent right genu varum, left genu valgus, right tibial procarvatum, and frontal bossing
#5	Poor initial compliance that subsequently improved	Moderate bilateral medullary nephrocalcinosis	90-223	No	Short stature, osteopenia, deep dental caries, frontal bossing, craniotabes, and bilateral genu varum
#6	Poor compliance	Resolved grade 1 nephrocalcinosis	Large parathyroid adenoma post total parathyroidectomy	No	Short stature, osteopenia, and frontal bossing
#7	Poor compliance	Grade 2-3 medullary nephrocalcinosis	80-119	Bilateral lateral distal hemiepiphysiodesis of the femur and proximal tibia	Short stature, osteopenia, sever bilateral genu varum, deep dental caries and

The Manifestations and Complications of X-linked Hypophosphatemia in Saudi Arabia: A Retrospective Study

Patient	Compliance to medication	Renal status	PTH (ng/L)*	Surgical correction	Skeletal and dental complications
					abscesses, and scaphocephaly craniosynostosis
#8	Poor initial compliance that subsequently improved	Grade 1 nephrocalcinosis	801-100	No	Short stature, osteopenia, sagittal craniosynostosis, proptosis and mild bilateral genu varum
#9	Poor compliance	Grade 1 nephrocalcinosis	Normal	No	Short stature, osteopenia, sagittal craniosynostosis and bilateral genu valgum
#10	Poor compliance	Normal	80-130	Corrective osteotomies	Short stature, osteopenia, sever bilateral genu varum
#11	Poor compliance	Grade 2 nephrocalcinosis	115-200	Multiple corrective osteotomies and epiphysiodesis	Short stature, osteopenia, and Persistent bilateral genu varum
#12	Poor compliance	Bilateral grade 3 nephrocalcinosis	200-400	Multiple corrective osteotomies with K-wire	Short stature, osteopenia, and Persistent bilateral genu valgum
#13	Poor compliance	Normal	Reaching 230	Multiple corrective osteotomies and epiphysiodesis	Short stature, osteopenia, dental deformities, bilateral genu varum and brachiocephalic craniosynostosis
#14	Unknown	Unknown†	120-180	Multiple corrective osteotomies with screws fixation	Short stature, osteopenia, and bilateral genu valgum
#15	Unknown	Normal	Normal	Multiple corrective osteotomies with screws fixation	Short stature, osteopenia, and bilateral genu varum
#16	Unknown‡	Bilateral grade 3 nephrocalcinosis	Normal	Unknown‡	Short stature and osteopenia.§
#17	Not on supplements	Normal	On thyroxine for hypothyroidism	Corrective osteotomy	Short stature, osteopenia, and kyphoscoliosis.

The Manifestations and Complications of X-linked Hypophosphatemia in Saudi Arabia: A Retrospective Study

Patient	Compliance to medication	Renal status	PTH (ng/L)*	Surgical correction	Skeletal and dental complications
#18	Poor compliance	Unknown†	93-112	No.	Short stature, osteopenia, and left genu valgum.
#19	Poor compliance	Normal	Normal	Corrective osteotomy	Short stature, osteopenia, and bilateral genu varum
#20	Good compliance	Normal	150-270	No	Short stature and osteopenia.§
#21	Good compliance	Normal	100-70	Multiple corrective osteotomies with screws fixation	Short stature, osteopenia, and bilateral genu varum
#22	Good compliance	Unknown†	Normal	Multiple corrective osteotomies with screws fixation	Short stature, osteopenia, and bilateral genu varum
#23	Good compliance	Normal	Normal	No	Short stature, osteopenia, and bilateral genu valgum
#24	Good compliance	Bilateral grade 1 nephrocalcinosis	Reaching 300	Multiple corrective osteo-tomies and epiphysiodesis	Short stature, osteopenia, and bilateral genu valgum

PTH: parathyroid hormone. *Normal PTH range: 15-65; †Renal ultrasound not done; ‡No follow up; §X-ray of leg not taken.

The Manifestations and Complications of X-linked Hypophosphatemia in Saudi Arabia: A Retrospective Study

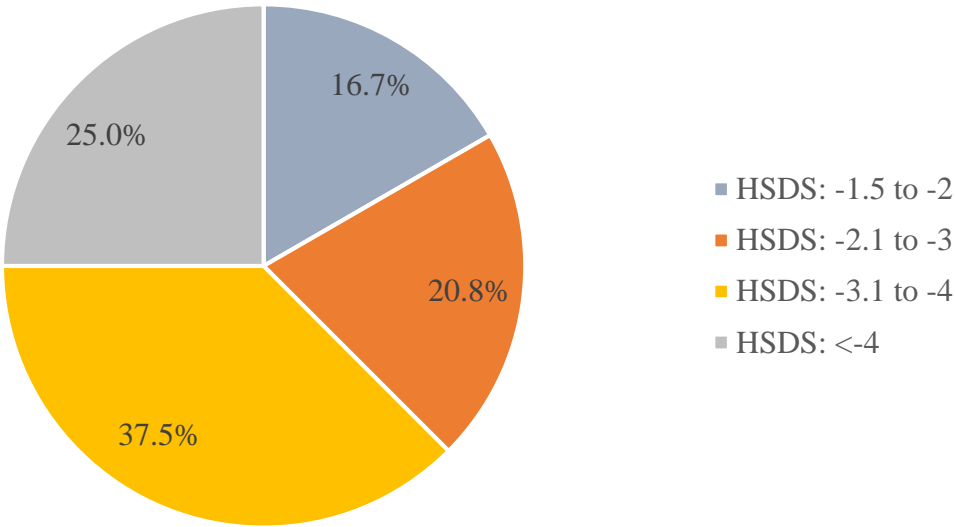


Figure 1: The Height Standard Deviation Score (HSDS) of patients in the study (N=24)

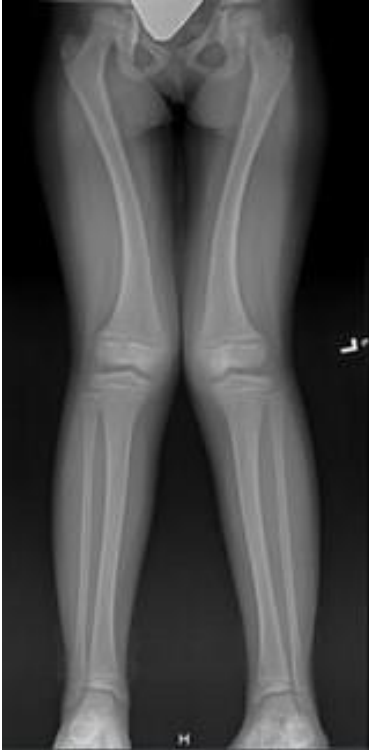

Figure 2: Radiograph of the lower limbs showing bilateral genu valgum in patient #1

The Manifestations and Complications of X-linked Hypophosphatemia in Saudi Arabia: A Retrospective Study

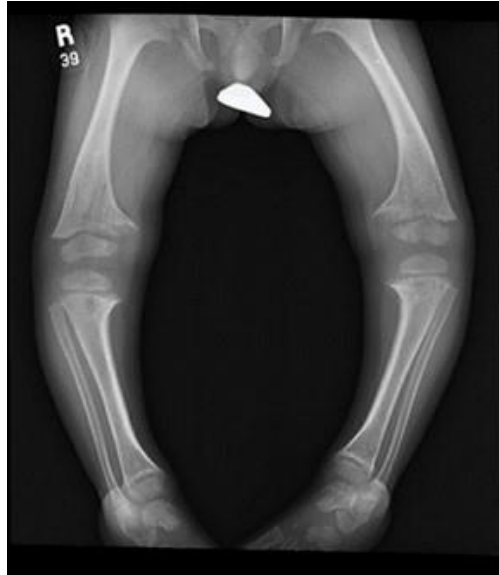

Figure 3: Radiograph of the lower limbs showing bilateral genu varum in patient #7

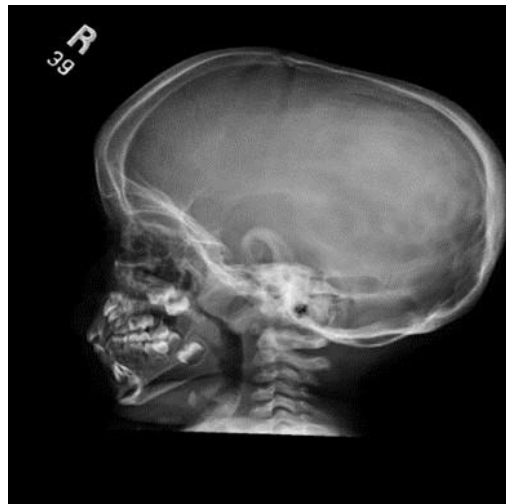

Figure 4: Radiograph showing the sagittal suture with elongation of the cranium in patient #7

The Manifestations and Complications of X-linked Hypophosphatemia in Saudi Arabia: A Retrospective Study

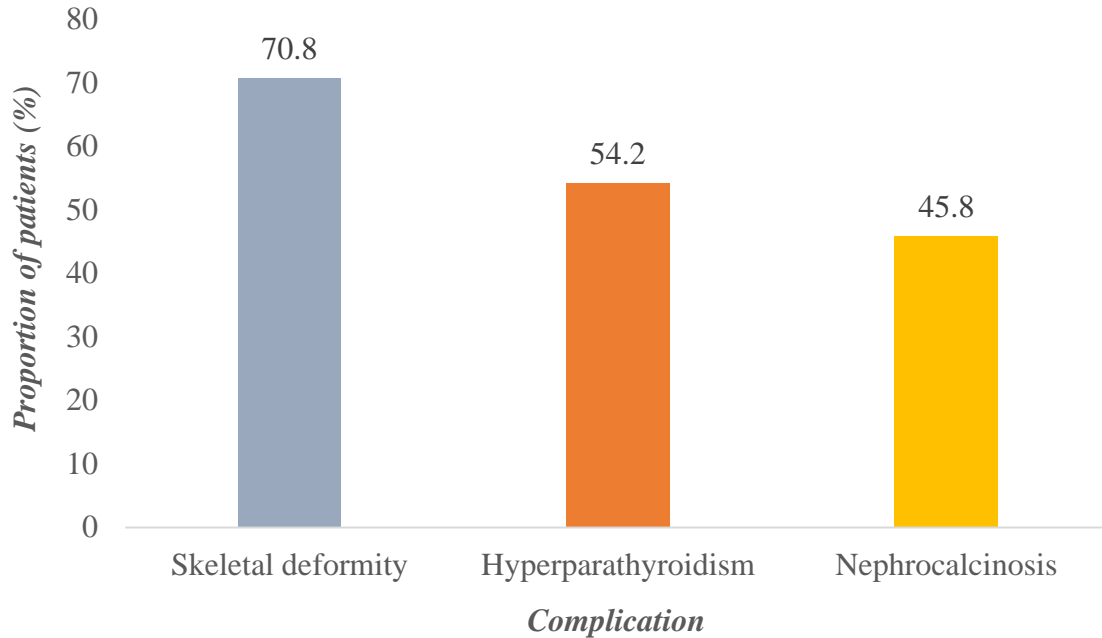


Figure (5): Commonly observed complications associated with hypophosphatemic rickets among patients in the study

And hyperparathyroidism [25, 26]. Furthermore, hyperparathyroidism can contribute towards the worsening of disease outcomes, causing patients to become more prone to fractures [22]. In this study, 54.2% of the patients had hyperparathyroidism and 4 (16.7%) were found to have parathyroid adenoma. Upon analysis of the patients' history, greater compliance to conventional therapy was observed among patients who had parathyroid adenoma. Additionally, patients with severely high PTH levels had undergone parathyroidectomy. In a US retrospective chart review of 84 XLH patients, 83.3% had secondary or tertiary hyperparathyroidism, 9.5% underwent parathyroidectomy and 75% of those undergoing parathyroidectomy had recurrent or persistent hyperparathyroidism [27]. It is thought that many of these patients developed secondary hyperparathyroidism during conventional therapy [27]. Higher incidences of renal stones have been observed in patients with XLH, regardless of therapy [28, 29]. In our study, nephrocalcinosis was detected in 45.8% of patients (predominantly grade 2/3). It was further noted that most of the patients suffering from nephrocalcinosis were committed to conventional therapy, which could be contributed to the precipitation of phosphate in the kidneys. However,

none of the patients had renal failure. High levels of nephrocalcinosis in XLH patients have been reported in other studies, with a Brazilian study reporting 38.5% of patients with nephrocalcinosis, with higher rates seen in pediatric patients, possibly a result of early initiation of phosphate supplementation [30]. The findings of this study demonstrated the characteristics of XLH patients who were followed up at KFSHRC in Saudi Arabia, and these findings were comparable to those from other studies [22- 30] in a similar setting. Generally, the characteristics and findings were somewhat similar among patients with no considerable differences. This is reflective of the general features and presentations that may be anticipated in patients with XLH.

Conclusion

In our study, all the XLH patients had significant complications, 54.2% suffering from endocrine complications and 70.8% having skeletal deformities. Lifelong treatment of XLH is critical since chronically low phosphate levels can progressively aggravate the disease burden. The study identified that use of conventional therapy was not successful in managing XLH, but instead, led to complications, such as the development of nephrocalcinosis and hyperparathyroidism. Therefore, there is a significant

The Manifestations and Complications of X-linked Hypophosphatemia in Saudi Arabia: A Retrospective Study

need for the use of other treatment modalities in XLH patients that are aimed at enhancing their quality of life.

Conflict of Interest

None

Funding

None

References

1. Beck-Nielsen SS, Mughal Z, Haffner D, Nilsson O, Levchenko E, Ariceta G, et al. FGF23 and its role in X-linked hypophosphatemia-related morbidity. *Orphanet J Rare Dis.* 2019; 14(1):58.
2. Beck-Nielsen SS, Brock-Jacobsen B, Gram J, Brixen K, Jensen TK. Incidence and prevalence of nutritional and hereditary rickets in southern Denmark. *Eur J Endocrinol.* 2009; 160(3):491–497.
3. Rafaelsen S, Johansson S, Ræder H, Bjercknes R. Hereditary hypophosphatemia in Norway: a retrospective population-based study of genotypes, phenotypes, and treatment complications. *Eur J Endocrinol.* 2016; 174(2):125–136.
4. Marik B, Bagga A, Sinha A, Hari P, Sharma A. Genetics of refractory rickets: identification of novel PHEX mutations in Indian patients and a literature update. *J Pediatr Genet.* 2018; 7(2):47–59.
5. Bitzan M, Goodyer PR. Hypophosphatemic rickets. *Pediatr Clin N Am.* 2019; 66(1):179–207.
6. Emma F, Cappa M, Antoniazzi F, Bianchi ML, Chiodini I, Eller Vaincher C, et al. X-linked hypophosphatemic rickets: an Italian experts' opinion survey. *Ital J Pediatr.* 2019; 45(1):67.
7. Carpenter TO, Imel EA, Holm IA, Jan de Beur SM, Insogna KL. A clinician's guide to X-linked hypophosphatemia. *J Bone Miner Res.* 2011; 26(7):1381–1388.
8. Linglart A, Biosse-Duplan M, Briot K, Chaussain C, Esterle L, Guillaume-Czitrom S, et al. Therapeutic management of hypophosphatemic rickets from infancy to adulthood. *Endocr Connect.* 2014; 3(1):R13–30.
9. NIH National Center for Advancing Translational Sciences, 2020. X-linked hypophosphatemia. Available from: https://rarediseases.info.nih.gov/diseases/12943/x-linked-hypophosphatemia#ref_10802 [accessed 27 July 2023; 15:03].
10. Gizard A, Rothenbuhler A, Pejin Z, Finidori G, Glorion C, de Billy B, et al. Outcomes of orthopedic surgery in a cohort of 49 patients with X-linked hypophosphatemic rickets (XLHR). *Endocr Connect.* 2017; 6(8):566–573.
11. Kocaoglu M, Bilen FE, Sen C, Eralp L, Balci HI. Combined technique for the correction of lower-limb deformities resulting from metabolic bone disease. *J Bone Joint Surg Br.* 2011; 93(1):52–56.
12. Matsubara H, Tsuchiya H, Kabata T, Sakurakichi K, Watanabe K, Tomital K. Deformity correction for vitamin D-resistant hypophosphatemic rickets of adults. *Arch Orthop Trauma Surg.* 2008; 128:1137–1143.
13. Carpenter TO, Insogna KL, Zhang JH, Ellis B, Nieman S, Simpson C, et al. Circulating levels of soluble klotho and FGF23 in X-linked hypophosphatemia: circadian variance, effects of treatment, and relationship to parathyroid status. *J Clin Endocrinol Metab.* 2010; 95(11):E352–357.
14. Imel EA, Gray AK, Padgett LR, Econs MJ. Iron and fibroblast growth factor 23 in X-linked hypophosphatemia. *Bone.* 2014; 60:87–92.
15. Jonsson KB, Zahradnik R, Larsson T, White KE, Sugimoto T, Imanishi Y, et al. Fibroblast growth factor 23 in oncogenic osteomalacia and X-linked hypophosphatemia. *N Engl J Med* 2003; 348:1656–1663.
16. Carpenter TO, Imel EA, Ruppe MD, Weber TJ, Klausner MA, Wooddell MM, et al. Randomized trial of the anti-FGF23 antibody KRN23 in X-linked hypophosphatemia. *J Clin Invest.* 2014; 124(4):1587–1597.
17. Kutilek S. Burosumab - a new drug to treat hypophosphatemic rickets. *Sudanese J Paediatr.* 2017; 17(2):71–73.
18. Food and Drug Administration, 2020. CRYSVITA® (burosumab-twza). Highlights of Prescribing Information. Available from: https://www.accessdata.fda.gov/drugsatfda_docs/label/2020/761068s0051bl.pdf [accessed 18 April 2023; 10:20].
19. Linglart A, Imel EA, Whyte MP, Portale AA, Högl W, Boot AM, et al. Sustained efficacy and safety of burosumab, a monoclonal antibody to FGF23, in children with X-linked hypophosphatemia. *J Clin Endocrinol Metab.* 2022;107(3):813–824.
20. Comprehensive Kidney Care Center, 2020. X-linked hypophosphatemic rickets. Available from: <https://www.rchsd.org/programs-services/nephrology/conditions-treated/x-linked-hypophosphatemic-rickets/#:~:text=Other%20secondary%20complications%20of%20XLH, infections%20abscesses%20and%20electrolyte%20abnormalities> [accessed 30 June 2023; 08:55].
21. Whyte MP, Schranck FW, Armamento-Villareal R. X-Linked Hypophosphatemia: a search for gender, race, anticipation, or parent of origin effects on disease expression in children. *J Clin Endocrinol Metab.* 1996; 81(11):4075–4080.
22. Cagnoli M, Richter R, Böhm P, Knye K, Empting S, Mohnike K. Spontaneous growth and effect of early therapy with calcitriol and phosphate in X-linked

The Manifestations and Complications of X-linked Hypophosphatemia in Saudi Arabia: A Retrospective Study

- hypophosphatemic rickets. *Endocrinol Rev.* 2017; 15(Suppl 1):119–122.
23. Rodríguez-Rubio E, Gil-Peña H, Chocron S, Madariaga L, de la Cerda-Ojeda F, Fernández-Fernández M et al. Phenotypic characterization of X-linked hypophosphatemia in pediatric Spanish population. *Orphanet J Rare Dis.* 2021; 16:104.
24. Mäkitie O, Doria A, Kooh SW, Cole WG, Daneman A, Sochett E. Early treatment improves growth and biochemical and radiographic outcome in X-linked hypophosphatemic rickets. *J Clin Endocrinol Metab.* 2003; 88(8):3591–3597.
25. Al-Juraibah F, Al Shaikh A, Al-Sagheir A, Babiker A, Al Nuaimi A, Al Enezi A, et al. Experience of X-linked hypophosphatemic rickets in the Gulf Cooperation Council countries: case series. *Endocrinol Diabetes Metab Case Rep.* 2024; 2024(2):23-0098.
26. Carpenter TO. New perspectives on the biology and treatment of X-linked hypophosphatemic rickets. *Pediatr Clin North Am.* 1997; 44(2):443-66.
27. DeLacey S, Liu Z, Broyles A, El-Azab SA, Guandique CF, James BC, et al. Hyperparathyroidism and parathyroidectomy in X-linked hypophosphatemia patients. *Bone.* 2019 ;127:386–392.
28. Connor J, Olear EA, Insogna KL, Katz L, Baker S, Kaur R, et al. Conventional therapy in adults with X-linked hypophosphatemia: effects on enthesopathy and dental disease. *J Clin Endocrinol Metab.* 2015; 100(10):3625–3632.
29. Arnaud C, Glorieux F, Scriver C. Serum parathyroid hormone in X-linked hypophosphatemia. *Science.* 1971; 173(3999):845–847.
30. Neto GPC, Yamauchi FI, Baroni RH, Bianchi MA, Gomes AC, Chammas MC, et al. Nephrocalcinosis and Nephrolithiasis in X-Linked Hypophosphatemic Rickets: Diagnostic Imaging and Risk Factors. *JES.* 2019; 3(5):1053–1061.