

## Ingested Magnets: A health hazard and the Role of laparoscopy. A tertiary center experience

Ahmed H. Al-Salem<sup>1</sup>, Moustafa Hamchou<sup>2</sup>, Hillal Matta<sup>2</sup>, Adnan Swid<sup>2</sup>, Bahjat Sahari<sup>2</sup>, Faisal Bawazir<sup>3</sup>

<sup>1</sup>Consultant pediatric surgeon, Dammam, KSA.

<sup>2</sup>Department of Surgery, Faculty of Medicine, Tawam Hospital, UAE.

<sup>3</sup>King Abdulaziz University for Health Sciences, College of Medicine, Jeddah, KSA

### ABSTRACT

Ingestion of magnets is becoming a common problem among children and teens and are known to be associated with serious complications that result from pressure necrosis and bowel perforation. We report a series of eight children with multiple magnets ingestion that resulted in complications including small bowel perforation and intestinal obstruction necessitating an emergency laparotomy and intestinal resection. The aim of this report is to raise awareness of the complications associated with magnet ingestion in children. The literature on the subject is also reviewed and early surgical intervention is recommended for multiple swallowed magnets. The role of laparoscopy in this regard is also stressed.

**Keyword:** Swallowed foreign bodies, swallowed magnets, intestinal necrosis and perforation, intestinal obstruction, laparoscopy.

### Introduction

Children are known to ingest inadvertently or intentionally a variety of foreign bodies such as coins, pins, screws, button batteries, or toy parts but fortunately the majority of them pass spontaneously without health consequences [1, 2, 3, 4, 5, 6, 7 and 8]. This however is not the case always and sometimes these swallowed objects can cause intestinal obstruction, perforation or bleeding. This is specially so if the objects are large or sharp. Magnets as swallowed foreign bodies pose a real danger to children [9, 10 and 11]. A single magnet most likely will pass through without causing any harm. However, if two or more magnets have been swallowed, attraction between them will result in serious complications. Rapid evaluation of children with swallowed magnets is critical and to avoid complications and these magnets must be identified and if more than one removed. This is a report of eight children who swallowed multiple magnets necessitating an emergency laparotomy and or

Laparoscopy because of intestinal obstruction and perforation.

### Case reports

Case 1: A 2-year-old female presented to our hospital complaining of abdominal pain, vomiting, and abdominal distension of two days duration. The vomiting was bile-stained. Clinically, the abdomen was mildly distended but soft and not tender. Plain abdominal x-ray showed dilated bowel loops with air fluid levels and foreign bodies (Figures 1A and 1B). She underwent emergency exploration. The ascending and transverse colon up to the splenic flexure was dilated due to a band compressing the distal part of the transverse colon. This band was divided and further exploration revealed an inflammatory mass with two bowel loops joining each other about 35 cm from the duodeno-jejunal junction. Exploration of this mass revealed a magnetic bracelet causing adhesion between two bowel loops leading to perforation of the intestine and fistula formation (Figure 2). About 25 cm of jejunum was resected and end to end anastomosis

Access this article online	
Quick Response Code:	Website: www.smh-j.com
	DOI: 10.54293/smhj.v1i1.12

**Address for correspondence:** Ahmed H. Al-Salem, consultant pediatric surgeon Urologist at Maternity and Children hospital, P. O. Box 61015, Qatif 31911, Saudi Arabia

**E-mail:** [ahsaalsalem@hotmail.com](mailto:ahsaalsalem@hotmail.com)

**Received:** 12 April 2021 | **Accepted:** 25 September 2021

This is an open access article by SMHJ is licensed under a Creative Commons Attribution 4.0 International License.

(<https://creativecommons.org/licenses/by/4.0>)

Please cite this article as: Al-Salem AH, Hamchou M, Matta H, Swid A, Sahari B, Bawazir FA. A Ingested Magnets: A health hazard and the Role of laparoscopy: A health hazard and the Role of laparoscopy. SMHJ [Internet]. 2021;1(1):37-41.

## Ingested Magnets: A health hazard and the Role of laparoscopy. A tertiary center experience.

was done. Post-operatively, she was well and was discharged home on the 6th post-operative day.

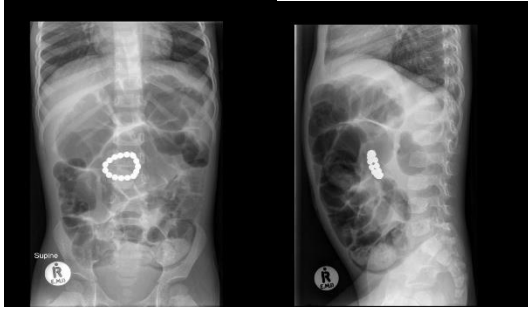


Figure 1A and 1B: Plain abdominal x-ray showing multiple magnets forming a chain.

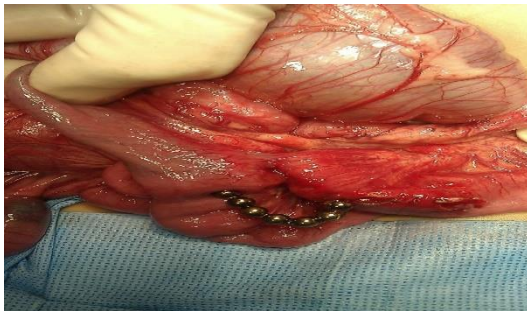

Figure 2: Intraoperative photograph showing multiple magnets forming a fistula between small bowel loops.

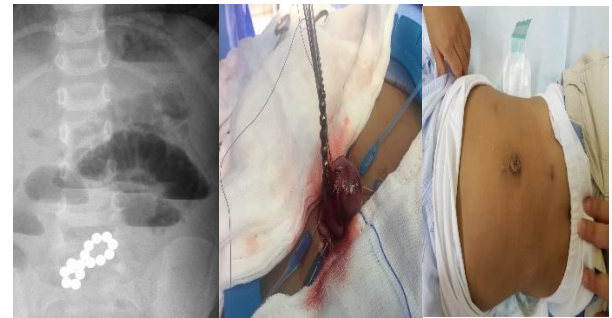
Case 2: A 7-year old male child presented because the parents saw the child swallow magnets. He was asymptomatic and plain abdominal x-ray showed one swallowed magnet in the left lower abdomen. This subsequently passed spontaneously. On the second day, he presented with sore throat and change of his voice. Plain x-ray of the neck revealed three foreign bodies (Figure 3). Upper endoscopy revealed two magnets and removed from the upper esophagus. The third magnet was not found and a repeat intraoperative fluoroscopy showed the third magnet most likely in the bronchus and this was removed from the left main bronchus using rigid bronchoscopy.

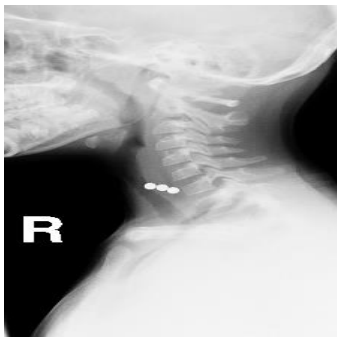

Figure 3: A lateral cervical x-ray showing three swallowed magnets, two were found in the esophagus and the third

one was found in the bronchus. They were held together but once the two esophageal magnets were removed, the third one slipped into the left bronchus.

Case 3: A 2-year old male presented with bilious vomiting and abdominal distension. His abdominal x-ray showed dilated bowel loops and air fluid levels. There were also multiple swallowed magnets. He underwent laparoscopy which revealed intestinal obstruction secondary to adherent magnets. The umbilical port was extended and the small intestines containing the magnets were delivered which was facilitated using a stitch (Figure 4A and 4B and 4C). A small enterotomy was performed and the magnets were removed. There was an area of necrotic small intestines and this was resected and primary end to end anastomosis was done.



Figures 4A, 4B and 4C: Intraoperative and postoperative clinical photographs showing multiple swallowed magnets removed via a laparoscopic assisted procedure. Note the excellent cosmetic appearance postoperatively.

Case 4: A 10-year old girl presented with a history of magnets ingestion. She was asymptomatic. Abdominal x-ray showed swallowed two magnets in the abdomen (Figure 5A). The patient underwent laparoscopy which revealed two magnets adherent between the transverse colon and small intestines. Both were removed via a laparoscopic enterotomy and primary closure of the opening in the colon and small intestines.

Case 5: An 8-year old presented with abdominal pain and vomiting. There was history of multiple magnets ingestion. Abdominal x-ray revealed multiple swallowed magnets (7 magnets) (Figure 5B). Diagnostic laparoscopy and laparoscopic enterotomy was done. There were adhesions which were released and the magnets were removed via the enterotomy. The enterotomy was closed primarily.

Case 6: A 2-year old male child presented 5 hours after swallowing magnets. He was complaining of abdominal pain. He vomited several times and the vomitus was yellowish in color. Abdominal x-ray showed swallowed three magnets with dilated small bowel loops (Figure 5C). He underwent laparotomy

which revealed intestinal obstruction with two loops of small intestine adherent to each other and also to the cecum. The three foreign bodies were removed through an enterotomy and cecostomy. There were two perforations in the small intestines, one at 120 cm from the ileocecal valve and the second one was 240 cm from the ileocecal valve. These were closed primarily. The cecostomy was closed primarily and an incidental appendectomy was done.

Case 7: A 13-year old male presented to the hospital with severe abdominal pain and vomiting which is brownish in color. He gave history of swallowing two magnets. Abdominal x-ray showed the magnets in the upper abdomen possibly in the stomach. Upper endoscopy was done. This revealed one magnet in the prepyloric area but it was not possible to remove it as it was adherent to the second magnet which was in the first part of jejunum. Laparoscopy was done and this showed no perforation. The second magnet was found 3cm distal to the ligament of Treitz. This was mobilized and the stomach magnet was removed endoscopically. The second magnet moved distally and was left to pass spontaneously. On follow-up, this passed spontaneously.

Case 8: A 2-year old male was referred to our hospital because he ingested three magnets. He was complaining of mild abdominal pain. Abdominal x-ray revealed swallowed three magnets most likely in the stomach. He underwent upper endoscopy which showed three magnets stuck to each other. The three magnets were removed successfully via the scope (Figures 5D, 5E and 5F).

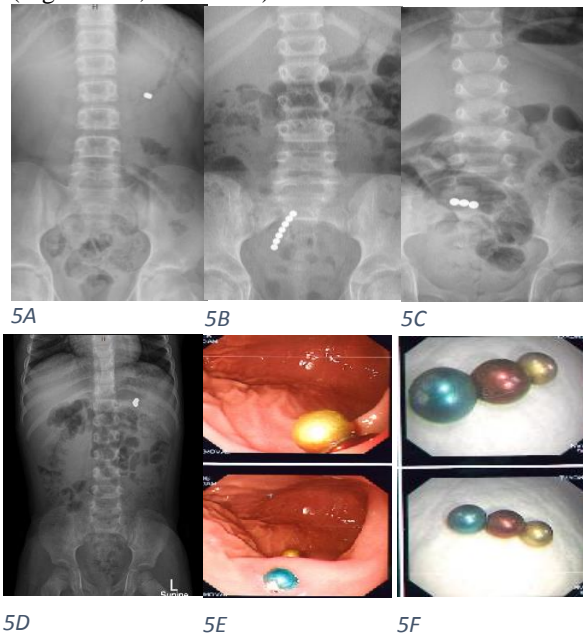


Figure 5A, 5B, 5C, 5D, 5E and 5F: Abdominal x-rays showing five patients with different swallowed magnets with and without intestinal obstruction.

## Discussion

Accidental ingestion of magnets, which was once rare, has become more common and a serious health problem among children and teens [9, 10, 11 and 12]. This is attributed to the widespread use of magnets in toys which makes them easily accessible to children specially toys where the magnetic parts could be detached easily. Add to this the use of magnets as body art and to mimic piercings of the tongue, lip, and nose and the wide spread use of small, round (about 3 to 6 mm in size) magnets marketed as “stress relief” (high-powered neodymium magnets) desk toys for adults. These are generally sold in sets of 100 or more which makes it difficult for parents to recognize if a few magnets have gone missing. The North American Society for Pediatric Gastroenterology, Hepatology and Nutrition in their survey reported that 50.4 percent of swallowed magnets are in patients between the ages of 1 and 6 years, while 33.6 percent are seen in children 6 to 12 years old [9, 11]. Some of these magnets are small and powerful and if more than one are swallowed they end up in different parts of the gastrointestinal tract. The strong magnetic force leads to attraction between them and they pull toward each other leading to pressure against the intestinal walls with subsequent pressure necrosis, perforation, fistula formation and intestinal obstruction [13, 14, 15 and 16].

Magnets pose a real danger to children and parents should be aware of this. Early recognition and surgical intervention can prevent significant morbidity and mortality. A single swallowed magnet will likely pass through without any harm. However, if two or more magnets have been swallowed, attraction between them may result in serious complications. To avoid this, rapid evaluation and emergency surgical intervention is recommended. It is important that physicians caring for these patients are made aware of the serious consequences of magnet ingestion and that they are distinct from most other types of foreign body ingestion. Two or more swallowed magnets should not be left to pass spontaneously like other swallowed foreign bodies. If the magnets are discovered early and are in the stomach, they can be removed endoscopically as in one of our patients. It was interesting that in one of our patients, three magnets were swallowed simultaneously, two of them went into the esophagus but the third one went into the trachea. They were held together but once the esophageal ones were removed endoscopically, the third one slipped into the left bronchus and was removed via a bronchoscope. The simultaneous ingestion of more than one magnet may lead to their attraction and adherence to each other in the stomach and can pass spontaneously or better they can be removed endoscopically. Once multiple swallowed

magnets pass beyond the stomach early surgical intervention is indicated to prevent serious life-threatening complications such as intestinal obstruction and intestinal perforation [13, 14 and 16]. These are removed via the classic laparotomy. The recent advances in minimal invasive surgery had made it possible to remove these magnets laparoscopically [17, 18, 19, 20, 21 and 22]. This is made easy as the magnets will be attracted to the laparoscopic instruments which facilitate their identification and removal. This is so even in the presence of intestinal perforation or obstruction as was shown in our patients.

### **Conclusion**

Swallowed magnets are a health hazard to children and delay in diagnosis and treatment can lead to serious complications. The policy of wait and see in the management of swallowed magnets should be avoided. Physicians caring for these patients should be aware of this and early referral to a specialized center is important and if more than one magnet were ingested, early surgical intervention is indicated to prevent serious life-threatening complications. Our series is limited to conclude from but laparoscopic removal of swallowed magnets is feasible and safe.

### **Conflict of Interest**

None

### **Funding**

None

### **Declaration of Patient consent**

The authors certify that they have obtained all appropriate patient consent forms.

### **References**

1. Kelley JE, Leech MH, Carr MG. A safe and cost-effective protocol for the management of esophageal coins in children. *J Pediatr Surg.* 1993 Jul; 28(7):900-898.
2. Pavlidis TE, Marakis GN, Triantafyllou A, Psarras K, Kontoulis TM, Sakantamis AK. Management of ingested foreign bodies: How justifiable is a waiting policy. *Surg Laparosc Endosc Percutan Tech.* 2008 Jun; 18(3):286-7.
3. Pryor HI 2nd, Lange PA, Bader A, Gilbert J, Newman K. Multiple magnetic foreign body ingestion: a surgical problem. *J Am Coll Surg.* 2007 Jul; 205(1):182-6.
4. Abbas MI, Oliva-Hemker M, Choi J, Lustik M, Gilger MA, Noel RA, et al. Magnet ingestions in children presenting to US emergency departments, 2002-2011. *J Pediatr Gastroenterol Nutr.* 2013 Jul; 57(1):22-18.
5. Litovitz T, Whitaker N, Clark L, White NC, Marsolek M. Emerging battery-ingestion hazard: clinical implications. *Pediatrics.* 2010 Jun; 125(6):1168-77.

6. Conners GP. Esophageal coin ingestion: going low tech. *Ann Emerg Med.* 2008 Apr; 51(4):373-4.
7. Peters NJ, Mahajan JK, Bawa M, Chhabra A, Garg R, Rao KL. Esophageal perforations due to foreign body impaction in children. *J Pediatr Surg.* 2015 Feb; 50(8):1260-3.
8. Litovitz T, Whitaker N, Clark L. Preventing battery ingestions: an analysis of 8648 cases. *Pediatrics.* 2010 Jun; 125(6):1178-83.
9. Haraguchi M, Matsuo S, Tokail H, et al. Surgical intervention for the ingestion of multiple magnets by children. *J Clin Gastroenterol.* 2004; 38:915-6.
10. Tay ET, Weinberg G, Levin TL. Ingested magnets: the force within. *Pediatr Emerg Care.* 2004; 20:466--7.
11. Hussain Sunny Z., Bousvaros. Athos, Gilger. Mark, et al. Management of Ingested Magnets in Children. *Journal of Pediatric Gastroenterology & Nutrition.* 2012; 55 (3): 239-242.
12. Kircher MF, Milla S, Callahan MJ. Ingestion of magnetic foreign bodies causing multiple bowel perforations. *Pediatr Radiol.* 2007 Sep; 37(9):933-6.
13. Alzahem AM, Soundappan SS, Jefferies H, Cass DT. Ingested magnets and gastrointestinal complications. *Pediatr Radiol.* 2006; 36(3):263-4.
14. Uchida K, Otake K, Iwata T, Watanabe H, Inoue M, Hatada T, Kusunoki M. Ingestion of multiple magnets: hazardous foreign bodies for children. *J Pediatr Surg.* 2005; 40(10):33-5.
15. Wildhaber BE, Le Coultre C, Genin B. Ingestion of magnets: innocent in solitude: harmful in groups. *Emerg Med J.* 2002; 19(1):71-3.
16. McCormick S, Brennan P, Yassa J, Shawis R. Children and mini-magnets: an almost fatal attraction. *Eur J Pediatr Surg.* 1995; 5(2):119-20.
17. Dutta S., Barzin A. Multiple magnet ingestion as a source of severe gastrointestinal complications requiring surgical intervention. *Arch Pediatr Adolesc Med.* 2008; 162 (2):125-123.
18. Butterworth J., Feltis B. Toy magnet ingestion in children: revising the algorithm. *J Pediatr Surg.* 2007; 42:5-3.
19. Shah S.K., Tieu T.T., Tsao T. Intestinal complications of magnet ingestion in children from the pediatric surgery perspective. *Eur J Pediatr Surg.* 2009; 19: 334-7.
20. Waters M.D, Teitelbaum H., Thorne V., Bousvaros A., Noel R.A., Beierle E.A. Surgical management and morbidity of pediatric magnet ingestions. *J Surg Res.* 2015; 199: 137-140.
21. Wooten KE, Hartin CW Jr, Ozgediz DE. Laparoscopic diagnosis of magnetic malrotation with fistula and volvulus. *JSLs.* 2012 Oct-Dec; 16(4):644-6.

Ingested Magnets: A health hazard and the Role of laparoscopy. A tertiary center experience.

22. Troy L. Spilde, Daniel J. Ostlie, Walter S. Andrews, George W. Holcomb. Minimally invasive management of gastrointestinal foreign bodies. *Pediatr Endosurgery Innovative Tech.* 2004; 8 (1): 69-65.