

## Surgery of Medial Epicondylitis (Golfer's Elbow), an Overview

Elsayed Shaheen<sup>1</sup>, Yousif J. Alsanawi<sup>2</sup>, Ali M. Alshaharni<sup>3</sup>, Faleh A. Alshahrani<sup>4</sup>, Bander H. Alqahtani<sup>5</sup>, Mohammed B. Altherwi<sup>6</sup>, Ahmad A. Alhamoud<sup>7</sup>, Mohammed Y. Asiri<sup>3</sup>, Mohammed K. Alenezi<sup>8</sup>, Mohammad S. Alamri<sup>3</sup>.

<sup>1</sup>Orthopedic Surgery Department, Faculty of Medicine, Al-Azhar University, Cairo, Egypt. Orthopaedic consultant at Andalusia hospitals, KSA. <sup>2</sup>Alomran general hospital (OGH), Alhasa, KSA. <sup>3</sup>Medical intern, King Khalid University, Abha, KSA. <sup>4</sup>General Practitioner, King Abdullah hospital, Bisha, KSA. <sup>5</sup>Medical Intern, Asser central hospital, abha, KSA. <sup>6</sup>General practitioner, King Fahad Central Hospital (KFCH), Jazan, KSA. <sup>7</sup>Orthopedic Surgery Resident, Aliman General Hospital, Riyadh, KSA. <sup>8</sup>General Practitioner, North Medical Tower, Arar, KSA.

### ABSTRACT


Golfer's elbow, also known as medial epicondylitis, is a common disease. When doing activities that include wrist flexion and forearm pronation, repetitive forced wrist extension and forearm supination can lead to flexor-pronator tendon degeneration. An ongoing pathologic process in the tendon can lead to structural failure, irreversible fibrosis, or calcification. The most common complaint from patients is chronic, medial-sided elbow pain that gets worse with everyday activity. During the late cocking or early acceleration stages of the throwing action, athletes may have symptoms that are particularly severe. Injections of corticosteroids, activity modification, and NSAIDs are all examples of nonsurgical supportive therapy. After the acute symptoms have subsided, attention is directed toward injury prevention and flexor-pronator mass rehabilitation. Patients with severe symptoms are often the only ones who receive open surgical procedures. Hence the study aimed to summarize and explain the evidences regarding surgical management of medial epicondylitis (golfer's elbow).

**Keyword:** Medial epicondylitis, Golfer's elbow, Injury, Surgical repair, Tendinosis.

### Introduction

Both athletes and non-athletes experience frequently elbow pain due to epicondylitis. Both the medial and lateral epicondyles can develop this condition, although posterior epicondylitis is not as frequently as lateral epicondylitis [1, 2]. The term "posterior epicondylitis," "Golfer's elbow" or "thrower's elbow," which are both often used terms to describe a flexor-pronator tendonitis at its placement on the medial humeral epicondyle. The forearm flexor and the medial epicondyle is the place where both pronator muscles start. Indicator teres, carpi radialis flexors palmaris longus, and flexor digitorum superficialis,

Which originate on the medial epicondyle, are all innervated by the median nerve. The ulnar nerve runs from the lateral to the posterior of the epicondyle, located within the cubital tube. The conjoined flexor tendon of the medial epicondyle of the humerus is produced by these five muscles, which all come from the same location. This three-centimeter-long tendon crosses the medial ulnohumeral joint, and runs parallel to the ulnar collateral ligament. At the elbow, the ulnar collateral ligament (UCL) and common flexor tendon serve as an additional stabiliser by stabilising flexion and valgus loads [3]. Because it causes aches and

Access this article online	
Quick Response Code:	Website: www.smh-j.com
	DOI: 10.54293/smhj.v2i3.52

**Address for correspondence:** Elsayed Shaheen, Orthopedic Surgery Department, Faculty of Medicine, Al-Azhar University, Cairo, Egypt. Orthopaedic consultant at Andalusia hospitals, KSA.

**E-mail:** [ssshaheen2007@yahoo.com](mailto:ssshaheen2007@yahoo.com)

**Received:** 19 October 2022 **Received in revised form:** 5 November 2022

**Accepted:** 6 November 2022

This is an open access article by SMHJ is licensed under Creative Commons Attribution 4.0 International License.

<https://creativecommons.org/licenses/by/4.0>

Please cite this article as: Elsayed Shaheen, Jasem AlSanawi Y, Madhaf Alshaharni A, Ayesha Mohammed Alshahrani F, Haif Alqahtani B, Bahkali Ali Altherwi M, Abdulsamad Ahmad Alhamoud A, Yahya M Asiri M, Khalil Alenezi M, Saleh Alamri M. The Surgery of Medial Epicondylitis (Golfer's Elbow), an Overview. SMHJ [Internet]. 2022;2(3):118-123. Available from: <https://www.smh-j.com/smhj/article/view/52>

## Surgery of Medial Epicondylitis (Golfer's Elbow), an Overview

Exhaustion across upper body; extremity, medial epicondylitis can result in a handicap or impairment [4, 5]. Medial epicondylitis is treated with inflammatory medication, massages, elbow supports, along with steroid injections prior to surgery [6]. The pillars of treatment are nonsurgical therapy and open surgical management. Recent research has examined the extracorporeal therapies, such as their effects surgical procedures have altered and shock wave treatment (ESWT) [7]. After a successful course of treatment, the majority of patients return to their regular jobs and activities. Chronic pain or recurring issues are the most common adverse effects, notwithstanding their rarity. Surgery-related complications can result in infection or harm to the ulnar or medial antebrachial cutaneous nerves. Pain is expected to become better, even if 20% of patients who have surgical therapy for refractory cases do not resume their previous level of sports activity [8].

### Methods

Study Design Review article. Data gathering surgical management for medial epicondylitis papers from all around the world were searched in the public databases Medline and PubMed. Elbow, decortications, medial epicondylitis, release with a widespread flexor origin, and surgical intervention were among the keyword search terms that were used. The sources list of each research would be checked for more supporting information. The project's importance, the paper's use of English, and the 10-year time limit were used as inclusion criteria. All other papers whose primary focus is not in one of these areas, as well as several research and reviews, were rejected under this criterion.

### Anatomy and pathology

The five forearm muscles that make up the flexor-pronator tendon are the flexor carpi radialis (FR), pronator teres (PT), and long-fingered palms and ulnar flexors (FCU), and the superficial flexor of the digits (Figure 1). In most elbows, the common flexor tendon (CFT), which measures about 3 cm in length, medially stretches across the ulnohumeral joint. It connects to the medial humeral tendon anterior epicondyle and the front bundle proximally of the ulnar collateral ligament (UCL), having its fibres parallel to the UCL. Particularly the ulnar head of the PT, confluent with the CFT in an area of the anteromedial joint capsule that is hyperplastic [7].

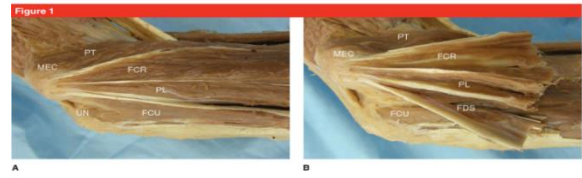

Figure 1: The ulnar nerve (UN), the medial epicondyle (MEC), and the anatomy of the flexor-pronator muscles, including the pronator teres (PT), flexor carpi radialis (FCR), palmaris longus (PL), flexor digitorum superficialis (FDS), and flexor carpi ulnaris (FCU), are shown in the images in A and B of a cadaver elbow [8].

Most writers agree that valgus stress at the elbow and the muscles are repeatedly loaded eccentrically involved in elbow flexion as well as elbow pronation are the main mechanisms of damage. Through eccentric contraction of the CFT, overhead throwing creates medial elbow strain with a valgus overload moment. This results in dynamic joint stabilisation. During ball release, concurrent elbow flexion as well as forearm pronation cause even more irregular strain on the tendon. The PT is the primary dynamic stabiliser and the musculotendinous unit that is most vulnerable to damage in medial epicondylitis, according to previous research. The palmaris longus is the only musculotendinous unit that has not been implicated by recent cadaver research, nonetheless [7]. Repeated supraphysiologic tension on the tendon causes microtrauma and degeneration. A stepwise pathologic tendon alteration has been discovered by histopathologic analysis. Repeated trauma causes peritendinous inflammation at first. An influx of vascular and fibroblastic cells components toward the tendon is known as angiofibroblastic hyperplasia. It is the outcome of ongoing damage. Angiofibroblastic hyperplasia, which eventually replaces the healthy tendon, causes structural failure and irreversible fibrosis or calcification. The UCL, which replicates the histologic structure and orientation of the CFT fibres, can eventually be subjected to activity that transfers forces deeper into the CFT [7].

### Prevalence

Lower frequency occurring compared to lateral epicondylitis, posterior epicondylitis makes up 10% to 20% of cases overall of epicondylitis [9]. Based on one study, 0.4% of people have the condition. The frequency is higher in females than in males and is highest in those between the ages of 45 and 64.

## Surgery of Medial Epicondylitis (Golfer's Elbow), an Overview

In various occupations, the incidence could range from 3.8% to 8.2%. In three out of every four situations, the dominant arm is involved [10- 14]. In a different research of US military members, the frequency was determined to be 5.6 per 1000 person-years [10]. The condition's natural course is self-limiting in 80% of patients, and they recover in one to three years [13]. Athletes are at risk for the potential onset of medial epicondylitis due to flaws in training, incorrect technique, apparatus, or functional risk factors such as weakness, endurance or adaptability [11]. Occupational risk factors include things like strenuous physical labour, a high smoking, body mass index, and the existence of comorbid conditions, as well as demanding psychosocial tasks [10, 12]. Cigarette usage and type 2 diabetes mellitus are universal risk factors. Obesity is linked to higher risk in women [14].

### **Diagnosis of medial elbow pain**

In their medical histories, patients often mention an acute traumatic injury, repeated elbow use, grasping, or valgus stress. Located on the lateral or ulnar side of the elbow they will describe throbbing pain that takes a downward path through the forearm and wrist from the epicondyle. It is frequently sly, even when serious harm is a potential. Throwing, grabbing, and forearm movements exacerbate the discomfort. This can be an athlete's heaving a throw motion, tennis serve or golf swing using the forearm. The pain is relieved by putting an end to all activity. According to the sufferer, they may feel stiff, weak, numb, or tingly. The ulnar nerve is distributed in the elbow. Chronic presentations may show an increased grip strength. Ulnar nerve issues may be present in 20% of patients [14]. Edema, erythema, or warmth may be present in acute cases; abnormalities are less likely to be found while investigating chronic cases. The affected area will be painful for the patient 5 to 10 millimetres distal and forward of the medial epicondyle, in particular around the conjoined muscles and tendons of the both the pronator teres and the flexor carpi radialis. When both pronation and flexion are resisted, the hand aches. When the patient affected arm could be weak. The motion is normally within a normal range [14]. There are active and passive parts to the medial epicondylitis test, sometimes known as the golfer's elbow test. With the arm extended and supinated, the patient resists wrist flexion during the active component. The wrist and elbow are extended as part of the passive component. If the patient acknowledges pain with this procedure, the test is considered positive [15, 16]. Use the Tinel's test to look for ulnar collateral as well as neuropathy. It's important to emphasise ligament, notably among throwers [14]. Additional diagnostic testing is typically not necessary because the clinical, the history and physical examination are required for diagnosis [17]. Imaging can help confirm the probable

diagnosis of medial epicondylitis and rule out alternative causes in cases when the clinical presentation is not clear-cut. The flexor-pronator tendons may develop calcification or traction osteophytes on plain radiographs [18]. Patients who have suddenly or traumatically started experiencing pain may find radiographs to be of particular benefit. Because clearly, growth plates are more susceptible to damage than tendons. Radiography might be a useful supplement in order to check for hidden bone issues in the juvenile population [19]. Magnesium-based imaging (MRI) is regarded as the most effective test for identifying medial epicondylitis [13]. The common flexor tendon sheath is thicker and has a higher T2 signal intensity in medial epicondylitis, according to the most accurate MRI results [20]. An MRI can also be used to excluding additional soft tissue or intraarticular issues conditions for instance, osteochondritis dissecans, loose bodies or damage to the ulnar collateral ligament [20]. The sensitivity and specificity of musculoskeletal ultrasonography (US) examination are 95.2% and 92%, respectively, to determine whether someone has medial epicondylitis [5]. The most typical ultrasonography results in the common flexor tendon include localised, hypoechoic alterations, ligament sheath thickening, full- or partial-thickness tears, Doppler-based neovascularization and cortical abnormalities where the medial epicondyle is [5,19]. Injuries to the ulnar nerve and ulnar instability of the collateral ligament as a result of valgus stress can both be evaluated by dynamic imaging investigations using ultrasound [21]. Generally speaking, people rarely experience medial elbow pain. Carpenters, plumbers, and "overhead" athletes are among the groups of persons who are more likely to develop this condition [22, 23]. Repetitive movements like wrist flexion and forearm pronation are frequently problematic at work [24]. The risk is greater for overhead throwers. Because of the elbow's valgus torque when the throw is being accelerated, which puts a lot of loads regarding the typical flexor pronator mass [25]. In addition to inadequate function of the medial collateral ligament (MCL), certain throwers may also have persistent impingement symptoms, also referred to as "chronic valgus overload syndrome." Although growing attenuation and failure could happen gradually, the diagnosis of the term "acute medial elbow instability" often straightforward and plain [26]. Medial elbow discomfort may be brought on by conditions affecting the ulnar nerve, such as nerve displacement and neuropathy are both possible. It has also been discovered that the medial antebrachial cutaneous nerve (MABCN) is associated to medial elbow discomfort [27]. Additional diagnoses that might result in medial elbow pain include osteochondritis dissecans of the trochlea, osteophytes

## Surgery of Medial Epicondylitis (Golfer's Elbow), an Overview

in the middle, fractures in the middle of the epicondyle, and ulnohumeral arthritis. The palmaris longus, flexor carpi radialis, and the pronator teres, the superficial flexor of the fingers, and the flexor vehicle ulnaris have all been connected to C6- and C7-related cervical radiculopathy which may lead due to an imbalance in the elbow's surrounding muscles, has been connected to the emergence of ME [28].

Physical exam: Certain patients might only suffer discomfort when performing physically taxing chores, which could stop them from looking an earlier appointment. ME is significantly more likely to develop in workers who handle objects weighing more 5 kg or more for longer more than twice as much time per day than ten times per day. Pain can make one side of the body weaker than the other in terms of wrist flexion and forearm pronation [29]. Concurrent twenty percent of patients may have ulnar neuritis. Radiographs can rule out additional causes of medial discomfort even though they are often unimpressive [30].

### Management

Conservative treatment: To begin conservative management, a medley of activities limitation, acupuncture, cold, pharmaceutical painkillers, anti-inflammatories, physical therapy, and iontophoresis is frequently employed. As local injections, steroids, platelet-rich plasma, and blood-filled dry needling injections have all been used, although the information now available implies that the outcomes might not considerably deviate by way of the natural history [31, 32]. When employing autologous blood treatment, the use of ultrasonography to direct the infusions may enhance their effectiveness. Nine out of ten individuals may benefit with conservative care, while those with persistent symptoms may be more likely to experience failure [32]. If the problem has not improved six months later of obtaining the suitable medical therapy, it is time to think about surgery. When persistent symptoms fail to improve with conservative therapy, we prefer further imaging tests (US or MRI) to rule out any other anomalies when there is paratendinous soft-tissue oedema and middle to high T2 signal strength, or high T2 signal strength within the common flexor tendon, are the most distinctive MRI findings of ME [33].

Surgical procedure: origin of the flexor-pronator mass is eroded is one among the many surgical options that have been addressed [34]. Similar to the medial epicondyle might be affected by lateral epicondylitis perforated to encourage restoring, and an anchor may be used to restore the muscle tears to their source. When the ulnar nerve becomes unstable during decompression, decompression and anterior transposition are procedures employed [30, 35].

The MABCN is protected during an open surgery, and subcutaneous dissection is carried out right in front of the medial epicondyle. The extensor pronator mass, which is split and separated in the chasm between the muscles of the pronator and flexor, is debrided and the diseased tissues are removed. In order to encourage recovery and regrowth regarding the bulk of the flexor pronator, the authors recommend utilising surgeon's anchor in conjunction with a minimal degree of bone decortication. A cadaver study, clinical trials, and research papers have all described arthroscopy for debridement. Investigations are uncommon and the majority of reports focus on open procedures [34]. The MCL and the ulnar nerve are two possible side effects of this therapy. After surgery, the arm is immobilised for a week in a comfortable splint before transitioning to a sling and gentle range-of-motion exercises [35]. While the inflammation is still present, pronation and vigorous wrist flexion should be prevented. Approximately 80% to 85% of open debridements are effective, but outcomes may be hampered by concomitant ulnar neuritis [30]. Preoperative ulnar neuritis or extended perioperative signs have been connected to a less favourable outcome, such as ongoing discomfort. While ME surgery is generally effective, some patients may still have discomfort afterward from hard exercise and may need to limit their free time [39]. Although nonsurgical treatment is the recommended course of action for medial epicondylitis, surgical surgery should be considered if nonsurgical methods are ineffective. One study [22] reported the surgical outcomes for medial epicondylitis that were tracked for more than 5 years. The investigation covered 63 medial epicondylitis instances between 2000 and 2010 and involved 55 individuals from the prior study. The conservative therapies lasted for at least a year, and steroid injections were administered more than twice before surgery. One surgeon handled all of the operations. The grades from Nirschl and Pettrone, the grip strength, the visual analogue scale (VAS) scores, the DASH scores, the Mayo Elbow Performance scores were looked at. Statistics were analysed using paired t tests [22]. It was stated that the typical VAS score dropped from 8.5 to 2.4. By Nirschl and Pettrone's grading, 27 elbows (or 43%) were exceptional, while 32 elbows (or 51%) were good. Mighty elbow DASH scores improved from 57 to 23, while performance ratings went up from 72 to 88. The mean grip strength on the afflicted side rose from 30 to 43 lb. It took an average of 2.8 months and 4.8 months, respectively, to start working out again. In one case, heterotrophic ossification did not lead to functional instability, which demonstrated that surgical therapy of medial epicondylitis may be an effective and secure choice when conservative treatment fails [22].

## Conclusion

In medial epicondylitis of the elbow, the musculotendinous roots at the medial epicondyle experience pathologic alteration. A successful long-term treatment for those with medial and lateral epicondylitis would ease pain for a sizable section of the population and lower healthcare expenses associated with managing a chronic condition. Surgery provides a great deal of subjective comfort, but there may still be objective strength limitations.

## Conflict of Interest

None

## Funding

None

## References

1. Leach RE, Miller JK. Lateral and medial epicondylitis of the elbow. *Clin Sports Med.* 1987;6(2):259-272.
2. McCarroll JR, Rettig AC, Shelbourne KD. Injuries in the amateur golfer. *Phys Sportsmed.* 1990;18(3):122-126. doi:10.1080/00913847.1990.11709999
3. Ollivierre CO, Nirschl RP, Pettrone FA. Resection and repair for medial tennis elbow. A prospective analysis. *Am J Sports Med.* 1995;23(2):214-221. doi:10.1177/036354659502300215
4. O'Dwyer KJ, Howie CR. Medial epicondylitis of the elbow. *Int Orthop.* 1995;19(2):69-71. doi:10.1007/BF00179962
5. Park GY, Lee SM, Lee MY. Diagnostic value of ultrasonography for clinical medial epicondylitis. *Arch Phys Med Rehabil.* 2008;89(4):738-742. doi:10.1016/j.apmr.2007.09.048
6. Lee AT, Lee-Robinson AL. The prevalence of medial epicondylitis among patients with C6 and C7 radiculopathy. *Sports Health.* 2010;2(4):334-336. doi:10.1177/1941738109357304
7. Amin NH, Kumar NS, Schickendantz MS. Medial epicondylitis: evaluation and management. *J Am Acad Orthop Surg.* 2015;23(6):348-355. doi:10.5435/JAAOS-D-14-00145
8. Alrabaa RG, Sonnenfeld J, Trofa D, Ahmad C. Elbow common flexor tendon repair technique. *Arthrosc Tech.* 2019;8(11):e1367-e1371. doi:10.1016/j.eats.2019.07.016
9. Shiri R, Viikari-Juntura E, Varonen H, Heliövaara M. Prevalence and determinants of lateral and medial epicondylitis: a population study. *Am J Epidemiol.* 2006;164(11):1065-1074. doi:10.1093/aje/kwj325
10. Wolf JM, Mountcastle S, Burks R, Sturdivant RX, Owens BD. Epidemiology of lateral and medial epicondylitis in a military population. *Mil Med.* 2010;175(5):336-339. doi:10.7205/milmed-d-09-00086
11. Plancher KD, Halbrecht J, Lourie GM. Medial and lateral epicondylitis in the athlete. *Clin Sports Med.* 1996;15(2):283-305.
12. Descatha A, Leclerc A, Chastang JF, Roquelaure Y. Medial epicondylitis in occupational settings: prevalence, incidence and associated risk factors. *J Occup Environ Med.* 2003;45(9):993-1001. doi:10.1097/01.jom.0000085888.37273.d9
13. Donaldson O, Vannet N, Gosens T, Kulkarni R. Tendinopathies around the elbow part 2: Medial elbow, distal biceps and triceps tendinopathies. *Shoulder Elbow.* 2014;6(1):47-56. doi:10.1111/sae.12022
14. Kiel J, Kaiser K. Golfers Elbow. *StatPearls.* 2022;1:1-3.
15. Orchard J, Kountouris A. The management of tennis elbow. *BMJ.* 2011;342:d2687. doi:10.1136/bmj.d2687
16. Polkinghorn BS. A novel method for assessing elbow pain resulting from epicondylitis. *J Chiropr Med.* 2002;1(3):117-121. doi:10.1016/S0899-3467(07)60015-9
17. Taylor SA, Hannafin JA. Evaluation and management of elbow tendinopathy. *Sports Health.* 2012;4(5):384-393. doi:10.1177/1941738112454651
18. Pitzer ME, Seidenberg PH, Bader DA. Elbow. *Med Clin North Am.* 2014;98(4):833-xiii. doi:10.1016/j.mcna.2014.04.002
19. Kijowski R, De Smet AA. Magnetic resonance imaging findings in patients with medial epicondylitis. *Skeletal Radiol.* 2005;34(4):196-202. doi:10.1007/s00256-005-0896-9
20. Reece CL, Susmarski A. Medial Epicondylitis. In: *StatPearls. Treasure Island (FL): StatPearls Publishing; April 30, 2022.*
21. Wu, V. J., Thon, S., Finley, Z., Bohlen, et al. Double-Row Repair for recalcitrant medial epicondylitis. *Orthop J Sports Med.* 2019;7(12):2325967119885608. doi:10.1177/2325967119885608
22. Shiri R, Viikari-Juntura E, Varonen H, Heliövaara M. Prevalence and determinants of lateral and medial epicondylitis: a population study. *Am J Epidemiol.* 2006;164(11):1065-1074. doi:10.1093/aje/kwj325
23. Shiri R, Viikari-Juntura E. Lateral and medial epicondylitis: role of occupational factors. *Best Pract Res Clin Rheumatol.* 2011;25(1):43-57. doi:10.1016/j.berh.2011.01.013
24. David TS. Medial elbow pain in the throwing athlete. *Orthopedics.* 2003;26(1):94-105. doi:10.3928/0147-7447-20030101-25
25. Lynch JR, Waitayawinyu T, Hanel DP, Trumble TE. Medial collateral ligament injury in the overhand-throwing athlete. *J Hand Surg Am.* 2008;33(3):430-437. doi:10.1016/j.jhsa.2007.12.015

## Surgery of Medial Epicondylitis (Golfer's Elbow), an Overview

26. Cesmebasi A, O'driscoll SW, Smith J, Skinner JA, Spinner RJ. The snapping medial antebrachial cutaneous nerve. *Clin Anat*. 2015;28(7):872-877. doi:10.1002/ca.22601
27. Nirschl RP, Ashman ES. Elbow tendinopathy: tennis elbow. *Clin Sports Med*. 2003;22(4):813-836. doi:10.1016/s0278-5919(03)00051-6
28. van Rijn RM, Huisstede BM, Koes BW, Burdorf A. Associations between work-related factors and specific disorders at the elbow: a systematic literature review. *Rheumatology (Oxford)*. 2009;48(5):528-536. doi:10.1093/rheumatology/kep013.
29. Vinod AV, Ross G. An effective approach to diagnosis and surgical repair of refractory medial epicondylitis. *J Shoulder Elbow Surg*. 2015;24(8):1172-1177. doi:10.1016/j.jse.2015.03.017
30. Suresh SP, Ali KE, Jones H, Connell DA. Medial epicondylitis: is ultrasound guided autologous blood injection an effective treatment? *Br J Sports Med*. 2006;40(11):935-939. doi:10.1136/bjism.2006.029983.
31. Cardone DA, Tallia AF. Diagnostic and therapeutic injection of the elbow region. *Am Fam Physician*. 2002;66(11):2097-2100.
32. Gabel GT, Morrey BF. Operative treatment of medial epicondylitis. Influence of concomitant ulnar neuropathy at the elbow. *J Bone Joint Surg Am*. 1995;77(7):1065-1069. doi:10.2106/00004623-199507000-00013
33. Zonno A, Manuel J, Merrell G, Ramos P, Akelman E, DaSilva MF. Arthroscopic technique for medial epicondylitis: technique and safety analysis. *Arthroscopy*. 2010;26(5):610-616. doi:10.1016/j.arthro.2009.09.017
34. Vangsness CT Jr, Jobe FW. Surgical treatment of medial epicondylitis. *J Bone Joint Surg Br*. 1991;73(3):409-411. doi:10.1302/0301-620X.73B3.1670439
35. Coombes BK, Bisset L, Brooks P, Khan A, Vicenzino B. Effect of corticosteroid injection, physiotherapy, or both on clinical outcomes in patients with unilateral lateral epicondylalgia: a randomized controlled trial. *JAMA*. 2013;309(5):461-469. doi:10.1001/jama.2013.129.