

# Clinical Outcomes of Surgical Management of Liver Abscess: A Systematic Review

Haneen I Brnawi<sup>1</sup>, Abdullah M. AL Madshush<sup>2</sup>, Tariq M. Alali<sup>2</sup>, Mohammed.I. Altidlawi<sup>2</sup>, Raghad H. Albalawi<sup>2</sup>, Abdullah H. Khoja<sup>2</sup>, Meshary D. Alzahrani<sup>2</sup>, Nouf Y. Alharbi<sup>2</sup>, Yasser S. Alzahrani<sup>2</sup>, Rahaf H. Albalawi<sup>2</sup>, Bandr M. Alenzi<sup>2</sup>, Anfal S. Alhawiti<sup>2</sup>, Rawan H. Albalawi<sup>2</sup>

<sup>1</sup>Consultant general surgery and assistant professor in Tabuk University, Tabuk, KSA.

<sup>2</sup>Medical Intern, Faculty of Medicine in Tabuk University, Tabuk, KSA.

## ABSTRACT

**Background:** Treatment for liver abscess, a major source of intra-abdominal infection, depends on how it presents. Over time, the method of treating PLA has changed, moving from open surgical drainage to percutaneous drainage assisted by imaging.

**Objectives:** This systematic review aims to investigate the efficacy of surgical approaches to manage liver abscesses.

**Methods:** PubMed, SCOPUS, Web of Science, and Science Direct, were systematically searched to include the relevant literature. Rayyan QRCI was used throughout this systematic approach.

**Results & interpretation:** included nine studies with a total of 632 patients. Antibiotics and/ or US or CT-guided PNA are the first line of treatment to manage liver abscesses. However, the relatively few individuals in whom aspiration was impossible because of thick pus, a septated or loculated abscess, or an abscess that had ruptured in any body cavity were indications for open or laparoscopic surgery. Additionally, we demonstrated that successful surgical procedures were linked to a significant decrease in mortality and a shorter hospital stay in patients with ruptured ALA. Only generalized peritonitis or further infections refractory to non-surgical treatment necessitate surgery. Additional randomized controlled studies involving a suitable patient population should be conducted to raise the level of evidence.

**Keyword:** Live abscess; Management; Open Surgery; Laparoscopy; Systematic review.

## Introduction

A hepatic parenchymal encapsulated suppurative collection characterizes a liver abscess, a common intra-abdominal infection cause [1]. Pyogenic liver abscesses (PLA) are more common in industrialized nations, but amoebic abscesses (ALA) are common in tropical regions and are regarded as a neglected disease by some authors [2, 3]. With an incidence of up to 26%, rupture is the primary consequence [4].

Different choices are available, and the therapy relies on how it is presented. Regardless of the stage of evolution, antibiotics are the first line of defense and should always be taken. However, for abscesses with a small diameter, anti-biotherapy can be used alone [5]. Percutaneous needle aspiration or catheter drainage are viable therapies with a strong track record of success in an event that the medical management alone is unsuccessful [6].

Access this article online	
Quick Response Code:	Website: www.smh-j.com
	DOI: 10.54293/smhj.v4i1.92

**Address for correspondence:** Haneen I Brnawi, Consultant general surgery and assistant professor in Tabuk University, Tabuk, KSA.

**E-mail:** [h-brnawi@ut.edu.sa](mailto:h-brnawi@ut.edu.sa)

**Received:** 11 October 2023 **Accepted:** 27 November 2023

This is an open access article by SMHJ is licensed under Creative Commons Attribution 4.0 International License.

<https://creativecommons.org/licenses/by/4.0>

Please cite this article as: I Brnawi H, Mohammed A AL Madshush A, Majed M Alali T, I. Altidlawi M, Hamdan A Albalawi R, Hisham M Khoja A, Defallah G Alzahrani M, Yousef A Alharbi N, Saadi M Alzahrani Y, Hamdan A Albalawi R, Mohammed F Alenzi B, Salem J Alhawiti A, Hussain Q Albalawi R. Clinical Outcomes of Surgical Management of Liver Abscess: A Systematic Review. SMHJ [Internet]. 2023;4(1):25-33.

# Clinical Outcomes of Surgical Management of Liver Abscess: A Systematic Review

Surgery is only indicated for burst liver abscesses, especially those that are in the peritoneal cavity [7]. One significant problem with open surgery was the greater related death rate [8]. According to clinical and radiological findings, ALA and PLA could be hard to tell apart. Traditionally, ALA aspiration displays an aspirate that resembles anchovy sauce. Trophozoites are infrequently seen in aspirates, microbiologically speaking. Additionally, despite having minimal utility to inhabitants in areas with high endemicity, serology for *E. histolytica* might be significant in travelers coming back from areas with high endemicity. If available, molecular and antigen tests can be helpful. More and more noninvasive tests, such as polymerase chain reactions, are being utilized to find *E. histolytica* DNA in bodily fluids like blood, pus, saliva, and urine [9]. If widely accessible, more recent procedures, as in lateral flow tests that employ serum markers, may be used to quickly and noninvasively diagnose ALA [10]. The purpose of this systematic study is to look into efficacy of surgical approaches to manage liver abscesses.

## Methods

Following the guidelines set out by PRISMA, or Preferred Reporting Items for Systematic Reviews and Meta-Analyses, this systematic review was conducted under strict guidelines [11].

**Study Plan and Length:** A systematic review was carried out in August and September 2023.

**Strategy for Search:** To discover the pertinent literature, a comprehensive search was conducted across four major databases: PubMed, SCOPUS, Science Web, and Science Direct. We restricted our search to English and considered all database's unique requirements. Some following keywords were converted into PubMed Mesh terms and used to find the pertinent studies; "Liver abscess," "Amebic liver abscess," "Pyogenic liver abscess," "Management," "Surgical approach," and "Surgery." The operators "OR" and "AND" in Boolean logic were used to match the required keywords. Publications with full text available in English, articles that could be downloaded for free, and human trials were among the search results.

### Selection criteria

**Inclusion criteria:** The following standards were taken into account for this review's inclusion:

- Study designs that investigated the efficacy of surgical approaches to manage liver abscesses.
- Studies that included the outcomes of surgical interventions only.
- Pyogenic or Amoebic liver abscesses.
- Recent studies showed in the last ten years (2014-2023).

- Language in English.
- Articles available for free.

**Exclusion criteria:**

- Percutaneous needle aspiration (PNA) alone was excluded.
- Children (<18 years).
- Case reports.

**Data extraction:** The search strategy's output was checked for duplication using Rayyan (QCRI) [12]. The researchers evaluated the titles and abstract relevance by modifying an inclusion/exclusion set of criteria to obtain the combined search results. The critics carefully examined each paper that met the criteria for inclusion. The writers covered techniques for resolving arguments. By a previously created data retrieval form, the authorized study was uploaded. Data on research titles, authors, year of study, nation, gender, participants, goals, and primary results were retrieved by the authors. The risk of bias evaluation was made on a different page.

**Data synthesis strategy:** To give a qualitative analysis of the findings and study components, summary tables were made utilizing data from relevant research. Once information needed for the systematic review were retrieved, the most productive way to use the selected data came from the study publications that were included.

**Bias assessment risk:** The ROBINS-I risk of bias assessment method for non-randomized treatment trials was used to assess the quality of the included studies [13]. Confounding, research participant selection, intervention classification, divergence from intended interventions, inadequate data, outcome evaluation, and choice of reported result were the seven areas that were assessed.

## Results

The systematic search produced 405 study papers in total, after 77 duplicates were eliminated. After 328 papers had their titles and abstracts checked, 288 research were deemed ineligible for inclusion. Out of the 40 reports that were requested to be retrieved, just one article was found. After 39 studies had been screened for full-text evaluation, nine had the incorrect population type and 21 had the incorrect research results, therefore they were eliminated. This systematic review contained nine research papers. (Figure 1) presents a synopsis of the research selection procedure. Characteristics of the included studies

The socio-demographic details of the research papers that are included are shown in (Table 1). Our results included nine studies with a total of 632 patients diagnosed with liver abscess. Three studies were conducted in China [14, 16, 22], four in India [15, 17, 19, 21], one in the UK [18], and one in Vietnam [20]. All of the included studies were retrospective in nature [14-22].

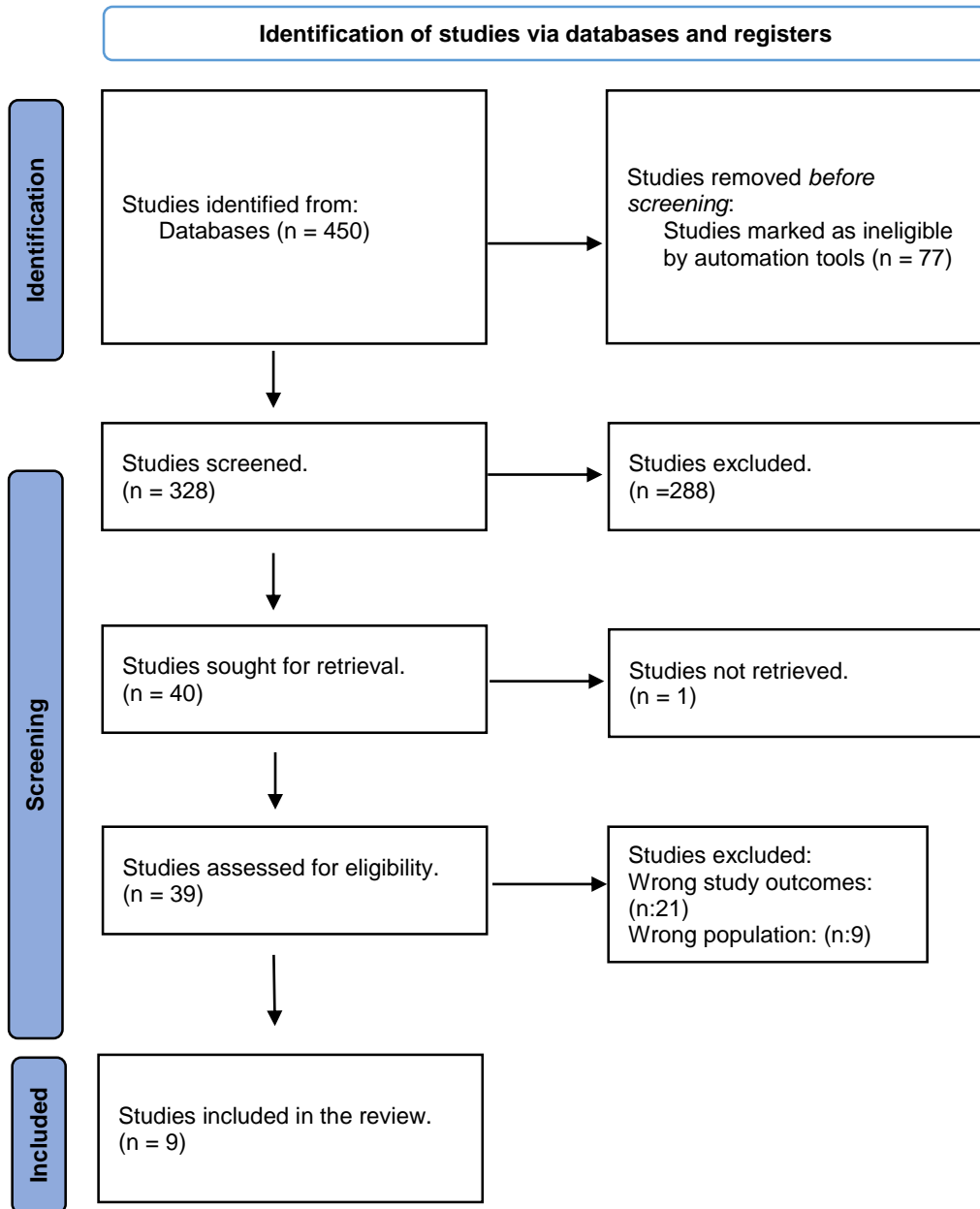


Figure 1: PRISMA flowchart summarizes the study selection process.

## Clinical Outcomes of Surgical Management of Liver Abscess: A Systematic Review

**Table (1):** Sociodemographic characteristics of the included participants.

Study	Study design	Country	Participants	Mean age (years)	Males (%)
<b>Li et al., 2022 [14]</b>	Retrospective cross-sectional	China	172	64.05 ± 13.94	100 (58.14)
<b>Perka et al., 2016 [15]</b>	Retrospective cross-sectional	India	30	47	NM
<b>Chee et al., 2019 [16]</b>	Retrospective cross-sectional	China	107	58.94 ± 11.3	74 (69.2)
<b>Maharaul et al., 2018 [17]</b>	Prospective	India	60	NM	32 (53.3)
<b>Kumar et al., 2022 [18]</b>	Retrospective cross-sectional	UK	82	16-91 (range)	NM
<b>Rajesh et al., 2016 [19]</b>	Retrospective cross-sectional	India	45	NM	NM
<b>Minh et al., 2019 [20]</b>	Retrospective cross-sectional	Vietnam	32	53.3 ± 15.3	NM
<b>Ojha and Tiwari, 2014 [21]</b>	Retrospective cross-sectional	India	73	NM	63 (86.3%)
<b>Tu et al., 2011 [22]</b>	Retrospective cross-sectional	China	31	35-73 (range)	13 (41.9)

\*NM=Not mentioned

**Table (2):** Clinical characteristics and outcomes of the included studies.

Study	Type of patients	Main outcomes	ROBI N-I
<b>Li et al., 2022 [14]</b>	PLA	Compared to PNA, the adverse effect is worse with PCA guided by ultrasound or CT. Although the severity of the illness in patients with liver abscesses was greater, neither mortality nor the length of the fever did significantly increase, showing that PNA is advantageous for severe patients due to its safety.	Moderate
<b>Perka et al., 2016 [15]</b>	ALA	In comparison to non-surgical treatments, surgical intervention is associated with a considerable reduction in mortality in patients with burst ALA. Surgery is only performed in cases of generalized peritonitis or when additional infections are present that are resistant to non-surgical treatment.	Moderate
<b>Chee et al., 2019 [16]</b>	PLA	A considerable increase in mortality is seen in patients with a liver abscess who also had diabetes mellitus, comorbidities of septic shock, respiratory failure, ARDS, DIC, and rupture of liver abscess at presentation. Despite these risk factors, this study found a low overall death rate for patients who had surgery for a liver abscess.	High
<b>Maharaj et al., 2018 [17]</b>	ALA	Surgery drainage is a more successful interventional therapy than conservative treatment because it reduces patient discomfort faster, shrinks the cavity more quickly, shortens the hospital stay, and reduces the likelihood of complications and recurrence. Benefits of percutaneous draining include rapid cavity size reduction, shorter time of medical treatment, and quick clinical improvement.	Moderate
<b>Kumar et al., 2022 [18]</b>	PLA	Lower mortality and shorter hospital stay result from giving patients the best care possible, which includes surgical drainage/resection as the initial treatment. To get these results, a liver unit must be consulted or transferred as soon as possible.	Moderate

Clinical Outcomes of Surgical Management of Liver Abscess: A Systematic Review

<b>Rajesh et al., 2016 [19]</b>	PLA	PNA has been identified as the initial course of treatment for hepatic abscess. This approach is quick, efficient, and affordable. This surgery is inexpensive since liver abscess affects low socioeconomic groups in a nation like India. For large abscesses, abscesses with thick viscous contents, and situations where PNA has failed, PCA should only be used as a last resort.	High
<b>Minh et al., 2019 [20]</b>	Ruptured liver abscess	Large and freely burst abscesses can be effectively treated by laparoscopic drainage, which reduces mortality, postoperative recovery time, and complications.	Moderate
<b>Ojha and Tiwari, 2014 [21]</b>	ALA and PLA	It was necessary to continuously drain the liver abscess with a Pigtail catheter and administer antibiotics if the abscess chamber was larger and frequently filled. Open surgical drainage was used to treat the relatively few individuals in whom aspiration was impossible because of thick pus, a septated or loculated abscess, or an abscess that had ruptured in any cavity of the body.	Moderate
<b>Tu et al., 2011 [22]</b>	PLA	The preferred method is systemic antibiotics combined with ultrasound-guided percutaneous catheter drainage. Laparoscopic or open surgery for the concurrent treatment of PLA and underlying biliary disease is safe and practical in selected patients with biliary PLA. Laparoscopic surgery has benefits for both the length of the postoperative hospital stay and postoperative recovery of gastrointestinal function.	Moderate

## Clinical Outcomes of Surgical Management of Liver Abscess: A Systematic Review

(Table 2) presents the clinical characteristics. Five studies included patients with PLA [14, 16, 18, 19, 22], two studies with ALA [15, 17], one with ruptured liver abscess [20], and one with both ALA and PLA [21]. Surgical intervention was successful and associated with a considerable reduction in mortality and shorter duration of hospital stay in patients with burst ALA. Surgery is only performed in cases of generalized peritonitis or when additional infections are present that are resistant to non-surgical treatment [15-20, 22]. One study reported that open surgical drainage was used to treat the relatively few individuals in whom aspiration was impossible because of thick pus, a septated or loculated abscess, or an abscess that had ruptured in any body cavity [21].

### Discussion

Depending on their size, ultrasonography or CT-guided drainage may or may not be used in conjunction with antibiotic therapy as the first line of treatment for liver abscesses. Drainage could be challenging to achieve in some circumstances. Due to its ability to provide effective, minimally intrusive care in these circumstances, laparoscopic surgery or open surgery is particularly valuable. In this review, we reported some indications for using surgical interventions, including the relatively few individuals in whom aspiration was impossible because of thick pus, a septated or loculated abscess, or an abscess that had ruptured in any body cavity [21]. Removal of the abscess, the following conditions call for drainage of a liver abscess in addition to medical managing: (1) a liver abscess in the left lobe; (2) an abscess surrounded by a thin (10 mm) border of hepatic parenchyma; (3) several liver abscesses; (4) an imminent rupture seen on imaging; and (5) failure to respond to medical intervention after three to five days. The evidence for upfront draining is debatable without these high-risk characteristics. Some randomized trials contrasting the use of drainage plus medical therapy with the use of medical management alone show a faster resolution of clinical and biochemical characteristics; however, other randomized trials do not [23]. A recent comprehensive analysis indicated that a combination strategy was only beneficial for abscesses larger than 5 cm in diameter and was ineffective for lowering fever, abscess healing, or length of hospital stay [24]. We also found that surgical interventions were successful and associated with a considerable reduction in mortality and shorter duration of hospital stay in patients with burst ALA. Surgery is only performed in cases of generalized peritonitis or when additional infections are present that are resistant to non-surgical treatment [15-20, 22]. Surgical and percutaneous methods for liver abscess drainage are

complementary. Prior to the 1970s, PLA was often treated with conservative measures or open surgical drainage, although the death rate was as high as 65% [25]. The preferred method for treating PLA is imaging-guided percutaneous catheter extraction in conjunction using antibiotics systemic, and the death rate is less than 10% [26, 27]. This is due to the advancement of imaging technology and efficient antibiotics with a broad spectrum. After percutaneous drainage fails or in patients with primary illnesses, including biliary PLA, abscess rupture, and so forth [26], an open surgical drainage of a liver abscess is recommended. A few benefits of surgical drainage include placement precision and concomitant abscess and primary illness treatment [28, 29]. According to current guidelines, liver abscesses smaller than 3 cm can be managed conservatively [30]. Aspirations for abscesses are successful and steer to decision in many patients. The likelihood of management success after each aspiration grows gradually with repeated aspirations [31]. When materials are few in poor countries, the use of needle aspiration is a desirable choice. It is better to avoid inserting a drain in LMICs because they can be troublesome to operate and a locate secondary infections. For the best method of managing liver abscesses in LMIC settings, more research is required. The time it takes to diagnose PLA affects the prognosis. Patients who receive a postponed diagnosis require drainage surgery for medical therapy. Poor outcomes were more prevalent for patients who presented with acute renal failure, acute respiratory failure and shock [32].

### Conclusion

Antibiotics and/ or US or CT-guided PNA are the first line of treatment to manage liver abscesses. However, the relatively few individuals in whom aspiration was impossible because of thick pus, a septated or loculated abscess, or an abscess that had ruptured in any body cavity were indications for open or laparoscopic surgery. Additionally, we demonstrated that successful surgical procedures were linked to a significant decrease in mortality and a shorter hospital stay in patients with ruptured ALA. Only generalized peritonitis or further infections that are refractory to non-surgical treatment necessitate surgery. Additional randomized controlled studies involving a suitable patient population should be conducted to raise the level of evidence.

### Conflict of Interest

None

### Funding

None

## Clinical Outcomes of Surgical Management of Liver Abscess: A Systematic Review

### References

1. Mavilia MG, Molina M, Wu GY. The evolving nature of hepatic abscess: a review. *Journal of clinical and translational hepatology*. 2016 Jun 6;4(2):158.
2. Kurland JE, Brann OS. Pyogenic and amebic liver abscesses. *Current gastroenterology reports*. 2004 Aug;6(4):273-279.
3. Kumanan T, Sujanitha V, Sreeharan N. Amoebic liver abscess: a neglected tropical disease. *The Lancet Infectious Diseases*. 2020 Feb 1;20(2):160-162.
4. Ndong A, Tendeng JN, Ndoye NA, Diao ML, Dieye A, Diallo AC, et al. Predictive risk factors for liver abscess rupture: a prospective study of 138 cases. *Archives of Clinical Gastroenterology*. 2020 Jan 25;6(1):001-5.
5. Trillos-Almanza MC, Gutierrez JC. How to manage: liver abscess. *Frontline Gastroenterology*. 2021 May 1;12(3):225-231.
6. Cai YL, Xiong XZ, Lu J, Cheng Y, Yang C, Lin YX, et al. Percutaneous needle aspiration versus catheter drainage in the management of liver abscess: a systematic review and meta-analysis. *Hpb*. 2015 Mar 1;17(3):195-201.
7. Bhatia M, Ali M. Ruptured liver abscess: analysis of 50 cases. *Medical Journal of Dr. DY Patil University*. 2017 Nov 1;10(6):532-535.
8. Priyadarshi RN, Prakash V, Anand U, Kumar P, Jha AK, Kumar R. Ultrasound-guided percutaneous catheter drainage of various types of ruptured amebic liver abscess: a report of 117 cases from a highly endemic zone of India. *Abdominal Radiology*. 2019 Mar 1;44:877-885.
9. Haque R, Kabir M, Noor Z, Rahman SM, Mondal D, Alam F, et al. Diagnosis of amebic liver abscess and amebic colitis by detection of *Entamoeba histolytica* DNA in blood, urine, and saliva by a real-time PCR assay. *Journal of clinical microbiology*. 2010 Aug;48(8):2798-2801.
10. Noordin R, Yunus MH, Saidin S, Mohamed Z, Corripio IF, Rubio JM, et al. Multi-laboratory evaluation of a lateral flow rapid test for detection of amebic liver abscess. *The American journal of tropical medicine and hygiene*. 2020 Dec;103(6):2233.
11. Page MJ, McKenzie JE, Bossuyt PM, Boutron I, Hoffmann TC, Mulrow CD, et al. The PRISMA 2020 statement: an updated guideline for reporting systematic reviews. *International journal of surgery*. 2021 Apr 1;88:105906.
12. Ouzzani M, Hammady H, Fedorowicz Z, Elmagarmid A. Rayyan—a web and mobile app for systematic reviews. *Systematic reviews*. 2016 Dec;5:1-0.
13. Jüni P, Loke Y, Pigott T, Ramsay C, Regidor D, Rothstein H, et al. Risk of bias in non-randomized studies of interventions (ROBINS-I): detailed guidance. *Br Med J*. 2016;355:i4919.
14. Li Y, Gao Q, Shi Y, Jiang J, Zhu X, Wang H, et al. Surgical management of pyogenic liver abscess: A retrospective cross-sectional multi-center study. *Researchsquare*. 20 October 2022;2(1):1-10
15. Perka S, Khajanchi M, Pothare A, Nandu V. Audit of patients with ruptured amoebic liver abscess and outcome of surgical versus non-surgical treatment. *International Surgery Journal*. 2016 Dec 10;3(4):2163-2166.
16. Chee M, Koh YX, Liew Y, Teo JY, Lee SY, Goh B, et al. Contemporary Surgical Management of Pyogenic Liver Abscess. *HPB*. 2019 Jan 1;21:S356.
17. Maharaul HH, Jain A, Bilwal H. A Clinical Study For Management Of Liver Abscess Present By Open Surgical Method In Tertiary Care Teaching Hospital. *Journal of Clinical Otorhinolaryngology, Head, and Neck Surgery* 2023;27:1
18. Kumar N, Sams E, Parry C, O'Reilly D, Duncan P, Allesandri G. Early Surgical Drainage for Pyogenic Liver Abscess in the Western World—A New Paradigm. *HPB*. 2022 Jan 1;24:S229.
19. Rajesh ST. Clinical Study of Liver Abscess and Its Management in Patients Admitted to Surgical Ward of KR Hospital Mysore (Doctoral dissertation, Rajiv Gandhi University of Health Sciences (India)). 2016;6(1):71-5.
20. Minh LQ, Tri LC, Minh Thuc VT, Huy HQ, Phuong HH, Vinh NQ. Laparoscopic surgery for intra-abdominal ruptured liver abscess: a study of 32 cases. *World J Surg Surgical Res*. 2019;2(20):1144.
21. Ojha A, Tiwari S. Clinical profile and management of liver abscess by USG guided aspiration in combination with antibiotics and surgery: a clinical study. *Journal of Evolution of Medical and Dental Sciences*. 2014 Jun 2;3(22):6105-6119.
22. Tu JF, Huang XF, Hu RY, You HY, Zheng XF, Jiang FZ. Comparison of laparoscopic and open surgery for pyogenic liver abscess with biliary pathology. *World journal of gastroenterology: WJG*. 2011 Oct 10;17(38):4339.
23. Sharma S, Ahuja V. Liver abscess: complications and treatment. *Clinical liver disease*. 2021 Sep;18(3):122.
24. Kumar R, Ranjan A, Narayan R, Priyadarshi RN, Anand U, Shalimar. Evidence-based therapeutic dilemma in the management of uncomplicated amebic liver abscess: A systematic review and meta-analysis. *Indian journal of gastroenterology*. 2019 Dec;38:498-508.
25. Roediger R, Lisker-Melman M. Pyogenic and amebic infections of the liver. *Gastroenterology Clinics*. 2020 Jun 1;49(2):361-377.
26. Abusedera MA, El-Badry AM. Percutaneous treatment of large pyogenic liver abscess. *The*



## Clinical Outcomes of Surgical Management of Liver Abscess: A Systematic Review

- Egyptian Journal of Radiology and Nuclear Medicine. 2014 Mar 1;45(1):109-115.
27. Sohn SH, Kim KH, Park JH, Kim TN. Predictors of mortality in Korean patients with pyogenic liver abscess: a single center, retrospective study. *The Korean Journal of Gastroenterology*. 2016 May 1;67(5):238-244.
28. Serraino C, Elia C, Bracco C, Rinaldi G, Pomero F, Silvestri A, et al. Characteristics and management of pyogenic liver abscess: A European experience. *Medicine*. 2018 May;97(19).
29. Rismiller K, Haaga J, Siegel C, Ammori JB. Pyogenic liver abscesses: a contemporary analysis of management strategies at a tertiary institution. *HPB*. 2017 Oct 1;19(10):889-893.
30. Su YJ, Lai YC, Lin YC, Yeh YH. Treatment and prognosis of pyogenic liver abscess. *International journal of emergency medicine*. 2010 Dec;3(4):381-384.
31. Yu SC, Lo RH, Kan PS, Metreweli C. Pyogenic liver abscess: treatment with needle aspiration. *Clinical radiology*. 1997 Dec 1;52(12):912-916.
32. Ko WC, Paterson DL, Sagnimeni AJ, Hansen DS, Von Gottberg A, Mohapatra S, et al. Community-acquired *Klebsiella pneumoniae* bacteremia: global differences in clinical patterns. *Emerging infectious diseases*. 2002 Feb;8(2):160.